

Original Article

Cerium nitrate enhances anti-bacterial effects and imparts anti-inflammatory properties to silver dressings in a rat scald burn model

Li-Wu Qian*, Andrea B Fourcaudot*, Ping Chen*, Kenneth S Brandenburg, Alan J Jr Weaver, Kai P Leung

Division of Combat Wound Repair, U.S. Army Institute of Surgical Research, JBSA-Fort Sam Houston, San Antonio 78234, Texas. *Equal contributors.

Received April 21, 2020; Accepted August 10, 2020; Epub August 15, 2020; Published August 30, 2020

Abstract: Current commercially available silver-based wound dressings such as silver-nylon have been used as anti-microbial barriers for burn and trauma care in combat conditions for over 10 years. However, these dressings do not stabilize the eschar or reduce its toxicity. Cerium nitrate (CN) solutions have been established clinically to stabilize the eschar by decreasing release of inflammatory mediators from burned tissue thereby allowing delayed excision and grafting. In this report, we tested the extent to which CN imparts CN benefits to silver dressings for temporizing treatments of burn wounds and enhancing anti-bacterial activity. Using a rat full-thickness scald burn model, we showed that CN enhanced the anti-bacterial effects of the tested silver-based dressings (Acticoat™, Mepilex™, and Silverlon®), while also imparting anti-inflammatory properties to these dressings. Compared to the use of silver dressings alone, CN significantly decreased the levels of IL-1 β and GRO/KC, and exhibited downward trending levels of IL-1 α , MIP-1 α , and bacterial bioburden within the wound. Based on our findings, we conclude that CN has the ability to expand and enhance the function of several silver dressings. We propose the use of CN in combination with silver dressings to stabilize burn wounds thereby allowing postponement of excision and grafting, most notably in scenarios where the standard of care is not feasible such as in combat situations, resource limited regions, and new emergent health care challenges as seen during the COVID-19 pandemic in which COVID-positive severe burn patients are not able to undergo surgery during an active outbreak.

Keywords: Cerium nitrate, silver dressings, burn, eschar, antibacterial, anti-inflammatory

Introduction

Burn wounds are highly susceptible to infections. In the absence of topical antimicrobials, the burn-injured tissues are rapidly colonized by the resident skin flora, which is mostly Gram-positive organisms, followed by endogenous Gram-negative bacterial cells and microorganisms from other sources (e.g. contaminated medical facilities) during the initial 72-hour post-burn period [1-3]. Among the various bacterial species that colonize the burn wound surface, *Staphylococcus aureus*, *Pseudomonas aeruginosa*, and *Klebsiella pneumoniae* are the most likely to result in invasive infections [4-7]. Wound infections resulting in exacerbated inflammation often derail the healing process and cause significant delays in wound closure resulting in excessive scar for-

mation [8]. In severe cases, highly invasive pathogens and their expressed toxins can exhaust host defenses and cause systemic complications such as sepsis, which contributes to the mortality observed in combat burn injuries. To minimize these undesired outcomes, the initial treatment focus for burn wounds is reducing the risk of infection [9].

In combat operations, often austere environments, timely debridement or excision of burned tissue-eschar- to decrease burn wound infection and secondary sepsis is not feasible [5, 10]. As an alternative to topical antimicrobial burn creams, which are not ideal for use at or near the point of injury in combat environments because of the substantial care burden of application as well as the amount required for treatment (400 g of cream to cover a 20%

total body surface area (TBSA) burn), various lightweight dressings containing antimicrobial silver have been developed [10, 11]. Some of these silver-based dressings have been deployed for use in combat areas [12, 13]. These dressings have several advantages, including easy application by less-experienced personnel, sustained release over several days decreasing the need for frequent dressing changes, less space requirements allowing more efficient storage and shipping, and tolerance to temperature extremes [10]. However, the use of silver dressings by themselves is not recommended for patients with extensively contaminated wounds or wounds with a heavy burden of devitalized tissue [10, 11]. This highlights the need to find treatment options to enhance the capability of silver dressings for combat deployment and other situations, to limit burn wound deterioration and allow for delayed excision and grafting when standard burn regimen is not possible.

Cerium in the form of cerium nitrate (CN) has been used for over 40 years to treat burn injuries. CN solution (40 mM) used in a single bathing of burn patients has been reported to mitigate burn-induced immunosuppression and deaths (retrospectively). Peripheral blood mononuclear cells (PBMCs) of patients who received CN bath, when stimulated *ex vivo*, produced IL-2 in the range of healthy normal persons as opposed to the low IL-2 levels produced by PBMC of patients who did not receive the CN bath [14, 15]. Using a rat model, a previous study showed that a single bathing of full-thickness (FT) burns (20% TBSA burn) in 40 mM CN solution for 30 minutes was as effective as a day two eschar excision with primary closure in mitigating burn-induced elevation of serum IL-6 and TNF on days 3 and 7 [16]. In the same model, Eski et al. [17] demonstrated that CN bathing of the burn wound for 30 minutes increased viable tissue on post-burn days 3 and 7.

Treatment of burns with CN in a cream with silver sulfadiazine (CN + SSD, commercially known as Flammacerium™) showed beneficial effects in burn wounds and is clinically approved to treat burn injuries in several European countries [18]. When applied to burn wounds, CN produced a “leatherlike” eschar that acts as a microbial barrier which could delay the need

for immediate excision and grafting [19]. This is advantageous for cases in which debridement or early eschar excision is not feasible. Our group also showed that a CN bath treatment stabilized burn eschar through the reduction of bacterial bioburden, Damage Associated Molecular Patterns (DAMPs), and inflammatory cytokines and chemokines [20]. CN has also been suggested to bind and prevent the release of toxic byproducts of thermal injury thereby decreasing inflammation [21]. Additionally, there are also reports showing that the addition of CN to silver sulfadiazine enhanced its antipseudomonal activity [22]. In this report, we show that CN enhanced the antibacterial activity of silver dressings and also enhanced anti-inflammatory effects on the burn wound, to a greater extent than the use of silver dressings alone. This proof of concept study will facilitate the development of products that prolong the prehospital management of burn-related injuries, thereby reducing casualties, on both the battlefield and in resource-limited regions.

Materials and methods

Animals

Research was conducted in compliance with the Animal Welfare Act, the implementing Animal Welfare regulations, and the principles of the Guide for the Care and Use of Laboratory Animals, National Research Council. The facility's Institutional Animal Care and Use Committee approved all research conducted in this study. The facility where this research was conducted is fully accredited by the AAALAC. Male Sprague-Dawley rats, 3-6 months old, weighing between 375-400 g were used for this study. The rats were acclimated in our animal facility at least one week prior to use.

Burn and treatment procedures

The rats were randomized into each treatment group (**Table 1**). One day prior to burn, the animals were anesthetized with 3% isoflurane and the dorsal skin was shaved and depilated with Nair (Church & Dwight, Ewing, NJ). To provide post-burn analgesia, Buprenorphine SR Lab (1.2 mg/kg, Zoopharm Pharmacy) was given subcutaneously. On the burn day, anesthesia was induced and maintained with 2.5-3% isoflurane for 15 minutes prior to the scald. The

Cerium nitrate enhances silver dressings

Table 1. List of treated and untreated groups and number of animals assigned to each group

Group	Burn	Wound treatment	Number of rats (POD3)	Number of rats (POD7)
Untreated	Yes	Sham	9	9
ACT	Yes	Acticoat® + water	9	9
ACT + CN	Yes	Acticoat® + CN	9	9
MX	Yes	Mepilex® + water	8	9
MX + CN	Yes	Mepilex® + CN	9	9
SL	Yes	Silverlon® + water	8	9
SL + CN	Yes	Silverlon® + CN	9	9
SSD	Yes	Silvadene®	9	9
SSD + CN	Yes	Flammacerium®	9	9
<i>Total</i>			79	81

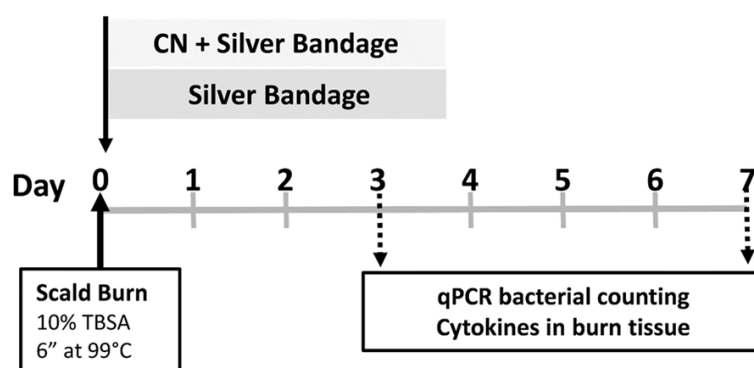


Figure 1. Schematic diagram of FT-burn and treatment approaches. All rats (one hundred sixty) received a 10% TBSA FT-burn and were randomized into 9 treatment groups. Each group consisted of 8-9 rats at each POD. The treatment effects on the burn wounds were evaluated by 16S rDNA-based bio-burden and burn wound pro-inflammatory cytokine profiles. The untreated group received no treatment post-burn aside from gauze dressing and Tegaderm under the rat jacket. The comparative studies were conducted using Acticoat™, Mepilex™, Silverlon®, and Silvadene® with or without CN wound bathing.

animals were then placed into a custom-built, insulated mold with a 5.3 × 9 cm opening [23, 24] equivalent to ~10% TBSA as calculated using the Meeh's formula [25]. The mold was immersed into water pre-heated to 99°C in a circulating water bath (Thermo Fisher Scientific, Precision CIR35, Newington, NH) for 6 seconds to create a FT burn on the dorsal skin [20, 23]. All treatments were applied immediately postburn (**Figure 1**). For the untreated control (sham) group, dry gauze was the primary dressing. For cream applications of SSD (Silvadene®, Pfizer, NY) or SSD + CN (Flammacerium™, Alliance, Spain, a generous gift from Dr. Terry Sadler of Alliance), a 1 mL pipette tip

was used to spread 4 ml of respective cream evenly over the entire burn wound. Thereafter, dry gauze was used to cover the treatment cream layer. For the subjects receiving silver dressing and CN or vehicle (water) treatments, rats maintained with 3% isoflurane were positioned supinely with the burned areas completely immersed in a container (12.5 × 12.5 × 2 cm) filled with 37°C filter-sterile 40 mM CN (Cerium Nitrate hexahydrate, Acros, NJ) or its vehicle, water, for 30 min. To prevent hypothermia, the bathing solutions were kept at 37°C by using a surgical heating block set to 40°C. For the respective silver dressing groups, the dressings were prepared and utilized according to manufacturer's instructions. Bathed wounds were then covered with either Acticoat™ (Smith & Nephew Medical, UK); Mepilex™ (Mölnlycke Health Care, Finland); or activated (i.e. immersed in water for 10 minutes per manufacturer's instruction) Silverlon® (Argentum Medical, IL). Silverlon® was overlaid by a damp dressing (either gauze soaked with 40 mM CN for CN treated animals (CN + silver) or gauze

soaked with water for vehicle control animals (silver + water)) to provide additional moisture for silver release. Tegaderm (3M Health Care, St. Paul, MN), a semi-occlusive bandage, was used to seal the treatments on the dorsal side of every rat. A rat jacket, which was custom designed and built in-house, was then placed on the rat to secure the dressings in place for the duration of the experiment [24]. Fluid resuscitation to aid in the recovery of the burned animals was injected intraperitoneally (i.p.) with 4 ml of lactated Ringer's solution immediately after the burn injury and every 12 hours thereafter for a total of 4 doses as calculated by the Parkland formula [26]. For

Silverlon® and CN or water treatment groups, gauze dressings were replaced with fresh ones soaked with either CN or water, respectively, at daily intervals for 2 days postburn with the rats under the inhalant anesthesia regimen described above. The burn wounds were photographed on post-operative days (PODs) 0, 3, and 7. Animals were anesthetized and euthanized at PODs 3 and 7; blood samples were drawn via cardiac puncture and wound samples were recovered with dermal biopsy punches (7 mm in diameter). The timeline of the experiment is shown in **Figure 1**.

Multiplex assay

A Bio-Plex Pro™ Rat Cytokine 23-Plex (Bio-Rad, Hercules, CA, USA) kit was used to assay and quantify 23 different inflammatory mediators (cytokines and chemokines) in burn wound samples on a Bio-Plex™ 200 System (Luminex 100/200, Austin, TX), as previously described [20, 27]. Briefly, burned skin (eschar) samples harvested by 7-mm biopsy punches (Acuderm, Fort Lauderdale, FL) were pulverized in liquid nitrogen using a Bessman Tissue Pulverizer (Spectrum, Inc., Rancho Dominguez, CA) and homogenized in tissue lysis buffer using a Tissue Tearer (IKA work, Inc., Wilmington, NC) according to the manufacturer's guidelines. After a freeze-thaw cycle and sonication, the samples were centrifuged and supernatants collected. Total protein concentrations of the supernatants were determined with a Pierce™ BCA protein assay kit (Thermo Scientific, Rockford, IL). Samples were normalized to 900 µg/mL protein and then assayed per manufacturer's instructions. Cytokines/chemokines in the wound samples were quantified using the BioPlex Manager 6.1 software and normalized to control for lot differences.

Quantification of total resident skin flora

A quantitative real-time PCR-based 16S rDNA assay was used to quantify total resident skin flora in wound samples [23, 24]. Briefly, four 7-mm biopsy punches from each burn wound were placed in MagNA Lyser Green Beads tubes (Roche Diagnostics GmbH, Mannheim, Germany), and homogenized with 1 mL phosphate-buffered saline (PBS) using a Fast-Prep®-24 Tissue Homogenizer (MP Biomedicals, LLC, Santa Ana, CA). Fifty microliters from each of the four biopsy homogenates were

pooled for DNA isolation. Bacterial DNA was isolated from each sample using the DNeasy Blood & Tissue Kit (Qiagen, Valencia, CA) according to the manufacturer's instruction. The amount of bacterial DNA from each sample was quantified using the universal primers and probe set (Forward 5-TCCTACGGGAGGC-AGCAGT-3; Reverse 5-GGACTACCAGGTATCT-AATCCTGTT-3' and probe (6FAM)-5-CGTATTAC-CGCGGCTGCTGGCAC-3-MGBNFQ) synthesized by Applied Biosystems (Carlsbad, CA). All real-time PCR reactions were performed on the StepOne Plus Real-Time PCR System (Applied Biosystems) using optical grade 96-well plates. Data obtained was analyzed using the StepOne software provided by Applied Biosystems. The amount of total genomic DNA in each sample was converted into genome copy number and normalized to the weight of the wound sample tissue.

Statistics

GraphPad Prism 7.03 (GraphPad Software, Inc., San Diego, CA) was used to analyze the data. Results were grouped according to one or two variables and compared using one- or two-way analysis of variance (ANOVA) with multiple comparisons test. The statistically significant difference among study groups was determined as $P \leq 0.05$. Data were plotted as the mean \pm standard error (SEM).

Results

Using our Rat Scald Burn Model [20, 23, 24, 27], we burned 162 rats and randomly assigned these burned rats into different treatment and sham (untreated) groups for the different time points. Nine rats were used per group per time point (**Table 1**). Two rats (one from water + Mepilex POD3 group and one from water + Silverlon POD 3 group) died before the end of experiments (**Table 1**). All other subjects reached the designed end points.

Cerium nitrate enhanced the anti-inflammatory effect of silver dressings

Without treatment, burn injury increased the local release of pro-inflammatory cytokines and chemokines. Silver dressings alone decreased the burn-induced cytokine expression to varying degrees. However, CN treatment in combination with the silver dressings demon-

Cerium nitrate enhances silver dressings

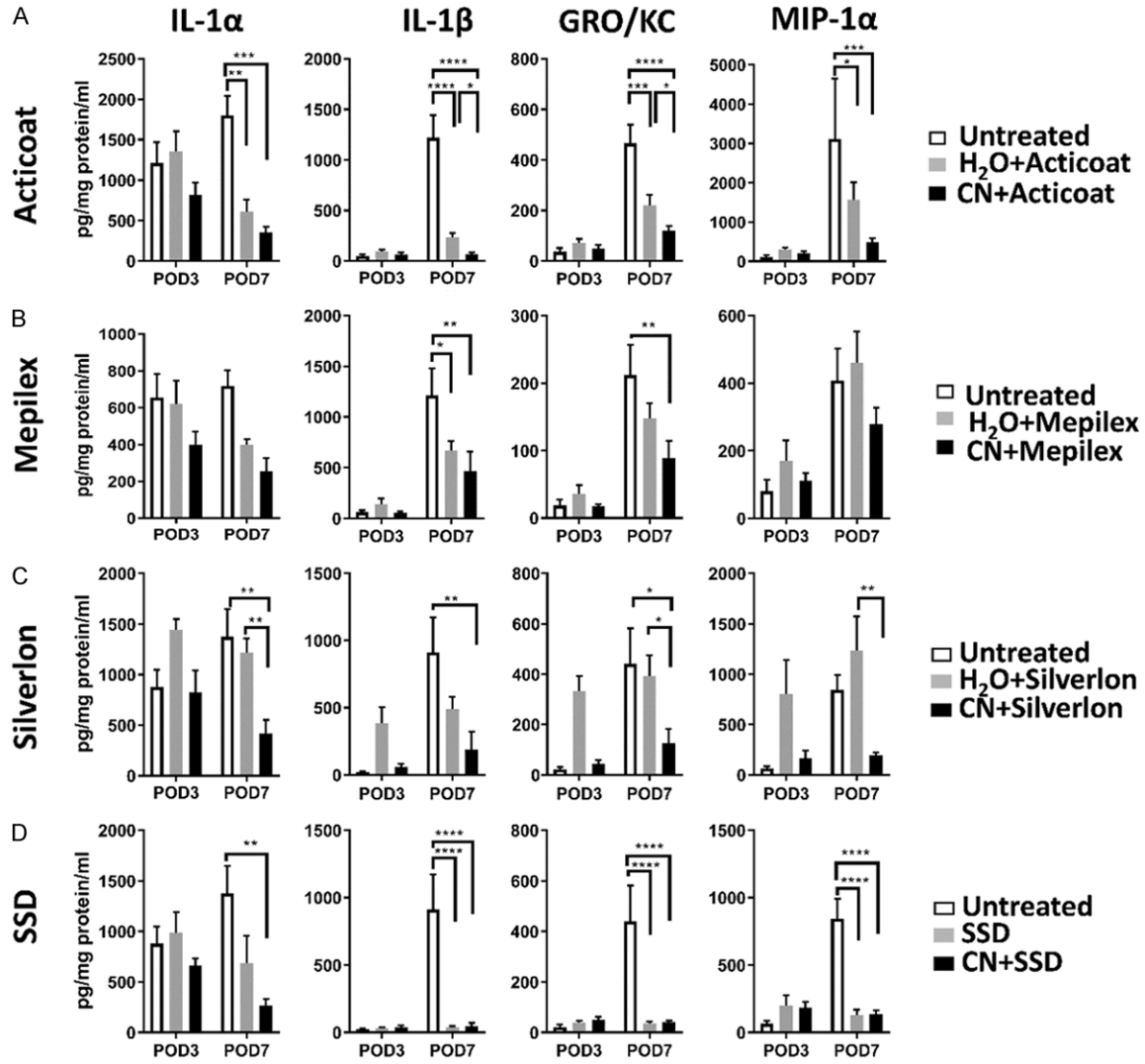


Figure 2. CN bath enhances the anti-inflammatory effect of silver dressings. The animals were euthanized at POD 3 and 7 and burn skin harvested. Following homogenization, the supernatants were evaluated for proinflammatory cytokines/chemokines. A. Acticoat™ inhibits burn-induced local increase of pro-inflammatory cytokines IL-1α, IL-1β and chemokines GRO/KC, MIP-1α. Combined use of CN bathing with Acticoat™ significantly enhances this effect. B. Mepilex™ mitigated burn-induced IL-1β and GRO/KC. Combined use of CN bathing with Mepilex™ enhanced its effects. C. Silverlon® by itself did not suppress burn-induced cytokines/chemokines. However, combined use of CN with Silverlon® significantly decreased all cytokines/chemokines as compared to the untreated controls. D. Silver Sulfadiazine cream (SSD) very significantly decreased burn-induced pro-inflammatory mediators in burn wounds. The combination of SSD and CN (Flammacerium) did not significantly enhance this effect. Based on two-way ANOVA with multiple comparisons, *P<0.05, **P<0.01, ***P<0.001, and ****P<0.0001, respectively.

strated an even greater decrease of these pro-inflammatory mediators than the dressings themselves alone (Figure 2).

Using the Acticoat™ dressing on burn wounds significantly reduced levels of IL-1α (Interleukin-1α; P<0.01 vs. untreated control), IL-1β (Interleukin-1β; P<0.0001 vs. untreated control), GRO/KC (growth-regulated oncogene/keratinocyte chemokine; P<0.001 vs. untreated

control), and MIP-1α (macrophage inflammatory protein-1α; P<0.05 vs. untreated control) at POD7. Combination of CN and Acticoat™ produced greater reductions in levels of IL-1β (P<0.05, Acticoat™ vs. Acticoat™ + CN) and GRO/KC (P<0.05, Acticoat™ vs. Acticoat™ + CN) (Figure 2A).

Mepilex™ treatment of burn wounds significantly reduced levels of IL-1β (P<0.05 vs. untreated

Cerium nitrate enhances silver dressings

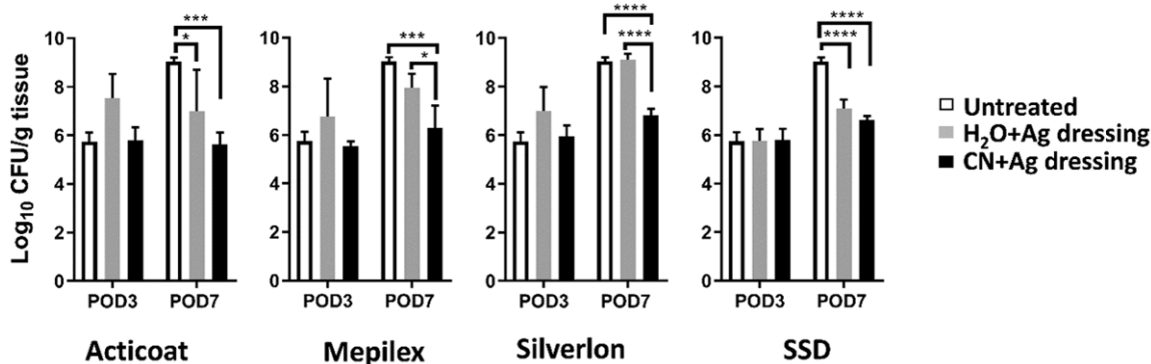


Figure 3. CN bath enhances the antimicrobial effect of silver dressings. The animals were euthanized at POD 3 and 7 and burn wounds harvested. The bioburden on burn skin was analyzed using real-time PCR with universal bacterial primers and probes. The data were transformed to log scale and then expressed as the mean \pm SEM for each group. * $P < 0.05$, *** $P < 0.001$, and **** $P < 0.0001$ comparing denoted treatment groups with two-way ANOVA with multiple comparison analysis.

control). While not significant, the levels of IL-1 α and GRO/KC trended lower. With the addition of CN to the treatment regimen, MepilexTM further reduced IL-1 β as well as significantly reducing GRO/KC release ($P < 0.01$ vs. respective untreated control) (Figure 2B).

Silverlon[®] alone did not suppress the burn-induced local release of the four proinflammatory cytokines and chemokines of interest and compared to the untreated controls, Silverlon[®] appeared to increase local release of these cytokines and chemokines (Figure 2C). However, combined with the use of CN, Silverlon[®] was effective in significantly reducing the levels of IL-1 α , IL-1 β , GRO/KC, and MIP-1 α ($P < 0.01$, $P < 0.01$, $P < 0.05$, and $P < 0.01$, respectively) as compared to the untreated controls (Figure 2C).

Silver Sulfadiazine (SSD, Silvadene[®]) and SSD + CN (FlammaceriumTM) creams demonstrated similar anti-inflammatory effect. Both SSD and SSD + CN displayed strong anti-inflammatory activity. This effect was demonstrated in the steep reduction of the burn-induced local levels of IL-1 α , IL-1 β , GRO/KC, and MIP-1 α . The levels of all four cytokines and chemokines were nearly abolished by day 7. However, there are no statistical differences between the two creams formulations (Figure 2D).

Cerium nitrate enhanced anti-bacterial effects of silver dressings

To evaluate the antimicrobial effect, the bacterial bioburden from each harvested burned

skin tissue was quantified using real time PCR with the universal primers and probe set. As demonstrated in Figure 3, the tested silver dressings showed varying anti-microbial effects as measured by PCR. Most notably at POD 7, CN treatment in combination with the silver dressings further significantly reduced the bacterial bioburden over the dressings themselves (Figure 3). Silvadene[®], which is the standard of care for controlling burn wound infection, served as an experimental control, also decreased the bioburden of the burned skin (Figure 3).

ActicoatTM alone effectively inhibited the burn-related proliferation of endogenous bioburden at POD7 ($P < 0.05$, ActicoatTM vs. untreated burn). Combined use of CN with ActicoatTM did not significantly enhance this effect at POD7 ($P < 0.001$, ActicoatTM + CN vs. untreated burn), however CN slightly enhanced the antimicrobial activity of ActicoatTM (Figure 3).

MepilexTM alone did not suppress the regrowth of skin flora post burn. However, combined use of CN with MepilexTM significantly reduced the bacterial counts as compared to both the untreated group ($P < 0.001$) and the MepilexTM only group ($P < 0.05$) at POD 7 (Figure 3).

Silverlon[®] treatment by itself also did not suppress growth of skin flora post burn. Conversely, adding CN to Silverlon[®] significantly attenuated skin bacterial proliferation compared to the untreated controls ($P < 0.0001$) and Silverlon[®] only group ($P < 0.0001$) at POD 7 (Figure 3).

SSD had a significant antibacterial effect against intrinsic skin bacteria ($P < 0.0001$ vs. untreated control). The addition of CN to the treatment (SSD + CN) showed similarly robust anti-bacterial efficacy, but was not significantly different from the SSD cream treatment alone (Figure 3).

Discussion

Burns are a common trauma seen in combat operations [28, 29]. Without treatment, severe burn wounds deteriorate. Eschar resulting from burned skin releases DAMPs (damage-associated molecular patterns) [20, 30, 31] and serves as a nidus of infection that also releases PAMPs (pathogen-associated molecular patterns) [30, 31]. Local and systemic inflammation results, with multiple organ dysfunction syndrome being the extreme result of the injury. The standard of care for the large second- and third-degree burn wounds is early excision of burned skin and grafting to close these wounds to limit complications, decrease inflammation, reduce infection risk, and improve outcomes [2, 32-34]. However, this is not always feasible in large-scale and highly contested combat operations; therefore, the need exists for prolonged field (pre-hospital) care. Prolonged field care of burn injuries that allows for delayed excision and grafting, involves temporizing treatments for large burn wounds to reduce the care burden, injury progression, systemic inflammation, and infection risk are required for reducing further morbidity or mortality.

Burn wound infections increase wound morbidity and mortality [5]. Current commercially available silver-based dressings such as silver-nylon dressings have been used as antimicrobial barriers for burn and trauma care under austere and combat conditions for over 10 years [10, 13]. In a retrospective study that analyzed a 10-year time span using Silverlon® during the evacuation of military burn casualties, Aurora *et al.* [12] reported the comparison of two patient cohorts (184 patients with Silverlon® vs. 803 patients with topical antimicrobial agents) and found that when compared with the topical antimicrobials, Silverlon® was not associated with a significant difference in pertinent burn-related complications [12]. Additionally, silver dressings are not effective

for care of wounds with a heavy burden of devitalized tissue [11]. These analyses suggested that silver dressings, while functioning effectively as anti-microbial barriers to reduce microbial colonization of burn wounds, lack the capability to temporize the burn wounds, reduce eschar toxicity, or limit wound progression.

For temporizing the burn injury another treatment modality other than silver is needed, and to this end, CN has been shown to be clinically effective. Treatment of burns with CN in a cream with silver sulfadiazine (CN + SSD, commercially known as Flammacerium™) resulted in a firm eschar that protects against bacterial ingress while allowing partial thickness wounds to heal [35, 36]. In animal studies, CN treatment in a solution can potentially: (a) limit signaling from burned tissue that causes immunosuppression [21], (b) directly limit pro-inflammatory signaling [16], and (c) protects against burn-injury progression [17]. In patients with severe burns, CN bath mitigates burn-induced immunosuppression and deaths [37]. The results collectively suggested that CN can temporize burn wounds by limiting their deterioration for improved burn wound outcomes.

Here, we tested the extent of a CN solution to impart its benefits on burn wounds treated with silver dressings. We investigated the anti-inflammatory and anti-bacterial effects of the commercially available silver dressings Acticoat™, Mepilex™, Silverlon® and a silver cream formulation (SSD) in use alone or in combination with CN. These tested silver dressings are among the most commonly used silver dressings for management of burn wound infections [13, 38-41]. Due to the type of silver species and base materials used in these slow release silver dressings [11, 38, 39, 41], they exhibit different physical properties, levels of silver contents, and antimicrobial activities [40, 42]. Silverlon®, a polymeric fabric coated with metallic silver, has a high silver content (5.46 mg/cm²) [11]. Acticoat™ consists of an absorbent rayon-polyester core sandwiched between two layers of nanocrystalline silver-coated high-density polyethylene (1.379 mg/cm²), which provides an initial large bolus of silver released to the wound followed by a sustained release [11, 38, 39]. Mepilex™ Ag is an adhesive (silicone-coated) silver dressing consisting of an absorbent polyurethane foam pad

Cerium nitrate enhances silver dressings

embedded with silver sulfate compound (1.2 mg/cm²) [39, 41].

Similar to earlier studies [40, 42], we found that these silver dressings alone had varying degrees of success in ameliorating the bio-burden and decreasing the levels of anti-inflammatory cytokines and chemokines. Every group of silver dressing tested, regardless of its physical properties or silver content and chemical form, had enhanced effects when used in combination with CN. Interestingly, among the test dressings, the CN benefits are most noticeable in Silverlon® as this dressing alone appeared to have a pro-inflammatory effect on the burn wounds as seen with elevated cytokines and chemokines and bioburden as compared to the untreated control. However, this pro-inflammatory effect was greatly reduced across all parameters tested with the addition of CN. The CN benefits observed are consistent with our earlier findings in which we demonstrated that CN bath alone reduces local neutrophil infiltration and pro-inflammatory mediators such as IL-1 β , IL-10, GRO-KC and MIP-1 α in rat FT burn wounds. At the systemic level, CN bath of burn wounds resulted in decreased circulating DAMPs - HMGB-1 and hyaluronan - in these burn rats [20]. Additionally, our findings also support the earlier notion that CN does not appear to compromise the anti-bacterial activity of silver [43] and may even, as shown here, enhance its bactericidal activity and improve its anti-inflammatory activity. Surprisingly, unlike the silver dressings, the addition of CN had no extra benefits on silver cream alone, which as shown in our study, that by itself was very efficient in reducing the cytokine and chemokine levels and bacterial burden of skin resident flora. However, in our other studies in which we challenged the rat burn wounds with *Pseudomonas aeruginosa* we observed that CN enhanced the anti-*Pseudomonas* activity of silver cream (data not shown).

The exact mechanisms of action for CN are not fully determined. The data support superficial connective tissue calcification [44], which may result from cerium displacing calcium from pyrophosphate to allow calcium deposition, analogous to the pyrophosphate-calcium interaction within cancellous or cortical bone [36]. Additionally, although cerium does not cross

the cytoplasmic membrane, it can extracellularly displace calcium, disrupting structures and enzymatic activities, which may underlie the reduced inflammation beneath the calcified eschar; e.g., by inactivating calcium-dependent inflammatory signaling molecules such as complement and S100 proteins (danger signals), or burn toxin [31]. We have initiated follow-up experiments to investigate the effect that CN may have on DAMP-mediated Toll-like Receptor (TLR) activation and its subsequent downstream effects on reduced oxidative burst, degranulation, and chemotaxis of blood neutrophils.

The current study demonstrates the additional benefits of adding CN to the use of silver dressings. This is a significant finding for clinical use, in that any differences in efficacy of several commercially available silver dressings can be potentially overcome by the addition of CN to the treatment regimen. Such a finding is exceptionally critical for situations where the standard burn wound excision and grafting is not feasible, such as the austere conditions of prolonged field care in our multi-domain operations on the battlefield, rural hospitals lacking resources, and in new and emergent health care crises such as the current COVID-19 pandemic. Early excision of the eschar in all these scenarios is not possible and therefore CN can greatly benefit burn wound care for both the warfighters on the frontline and civilian patients alike.

DoD disclaimer

The views expressed in this article (book, speech, etc.) are those of the author(s) and do not reflect the official policy or position of the U.S. Army Medical Department, Department of the Army, DoD, or the U.S. Government.

Acknowledgements

This work was supported in part through the Congressionally Directed Medical Research Programs, U.S. Army Medical Research and Development Command, Combat Casualty Care Research Directorate (Proposal# G_06-2017) and the Naval Medical Research Center's Advanced Medical Development program [MIPR N3239815MHX040]. Flammacerium™ is a generous gift from Dr. Terry Sadler of Alliance Pharma PLC, UK.

Disclosure of conflict of interest

None.

Address correspondence to: Dr. Kai P Leung, Capability Area Manager for Severe Burns, Division of Combat Wound Repair, U.S. Army Institute of Surgical Research, 3698 Chambers Pass Bldg 3610, JBSA Fort Sam Houston 78234-7767, Texas. Tel: 210-539-3803; E-mail: kai.p.leung.civ@mail.mil

References

- [1] Altoparlak U, Erol S, Akcay MN, Celebi F and Kadanali A. The time-related changes of antimicrobial resistance patterns and predominant bacterial profiles of burn wounds and body flora of burned patients. *Burns* 2004; 30: 660-664.
- [2] Barret JP and Herndon DN. Effects of burn wound excision on bacterial colonization and invasion. *Plast Reconstr Surg* 2003; 111: 744-752.
- [3] Revathi G, Puri J and Jain BK. Bacteriology of burns. *Burns* 1998; 24: 347-349.
- [4] Bayat A, Shaaban H, Dodgson A and Dunn KW. Implications for burns unit design following outbreak of multi-resistant acinetobacter infection in ICU and burns unit. *Burns* 2003; 29: 303-306.
- [5] Church D, Elsayed S, Reid O, Winston B and Lindsay R. Burn wound infections. *Clin Microbiol Rev* 2006; 19: 403-434.
- [6] Mayhall CG, Lamb VA, Gayle WE Jr and Haynes BW Jr. Enterobacter cloacae septicemia in a burn center: epidemiology and control of an outbreak. *J Infect Dis* 1979; 139: 166-171.
- [7] Sherertz RJ and Sullivan ML. An outbreak of infections with acinetobacter calcoaceticus in burn patients: contamination of patients' mattresses. *J Infect Dis* 1985; 151: 252-258.
- [8] Baker RH, Townley WA, McKeon S, Linge C and Vijn V. Retrospective study of the association between hypertrophic burn scarring and bacterial colonization. *J Burn Care Res* 2007; 28: 152-156.
- [9] Kauvar DS, Acheson E, Reeder J, Roll K and Baer DG. Comparison of battlefield-expedient topical antimicrobial agents for the prevention of burn wound sepsis in a rat model. *J Burn Care Rehabil* 2005; 26: 357-361.
- [10] Cancio LC, Barillo DJ, Kearns RD, Holmes JH 4th, Conlon KM, Matherly AF, Cairns BA, Hickerson WL and Palmeri T. Guidelines for burn care under austere conditions: surgical and nonsurgical wound management. *J Burn Care Res* 2017; 38: 203-214.
- [11] D'Avignon LC, Chung KK, Saffle JR, Renz EM and Cancio LC; Prevention of Combat-Related Infections Guidelines Panel. Prevention of infections associated with combat-related burn injuries. *J Trauma* 2011; 71 Suppl 2: S282-9.
- [12] Aurora A, Beasy A, Rizzo JA and Chung KK. The use of a silver-nylon dressing during evacuation of military burn casualties. *J Burn Care Res* 2018; 39: 593-597.
- [13] Barillo DJ, Pozza M and Margaret-Brandt M. A literature review of the military uses of silver-nylon dressings with emphasis on wartime operations. *Burns* 2014; 40 Suppl 1: S24-S29.
- [14] Allgower M, Schoenenberger GA and Sparkes BG. Pernicious effectors in burns. *Burns* 2008; 34 Suppl 1: S1-S55.
- [15] Sparkes BG. Mechanisms of immune failure in burn injury. *Vaccine* 1993; 11: 504-510.
- [16] Deveci M, Eski M, Sengezer M and Kisa U. Effects of cerium nitrate bathing and prompt burn wound excision on IL-6 and TNF-alpha levels in burned rats. *Burns* 2000; 26: 41-45.
- [17] Eski M, Ozer F, Firat C, Alhan D, Arslan N, Senturk T and Isik S. Cerium nitrate treatment prevents progressive tissue necrosis in the zone of stasis following burn. *Burns* 2012; 38: 283-289.
- [18] Garner JP and Heppell PS. The use of flammacerium in British burns units. *Burns* 2005; 31: 379-382.
- [19] Monafu WW, Tandon SN, Ayvazian VH, Tuschmidt J, Skinner AM and Deitz F. Cerium nitrate: a new topical antiseptic for extensive burns. *Surgery* 1976; 80: 465-473.
- [20] Qian LW, Evani SJ, Chen P, Brandenburg KS, Weaver AJ, Fourcaudot AB, Abercrombie JJ, Sebastian EA and Leung KP. Cerium nitrate treatment provides eschar stabilization through reduction in bioburden, DAMPs, and inflammatory cytokines in a rat scald burn model. *J Burn Care Res* 2020; 41: 576-584.
- [21] Kistler D, Hafemann B, Schoenenberger GA and Hettich R. Increased survival rates by topical treatment of burns with cerium nitrate. *Eur Surg Res* 1990; 22: 283-290.
- [22] Dai T, Huang YY, Sharma SK, Hashmi JT, Kurup DB and Hamblin MR. Topical antimicrobials for burn wound infections. *Recent Pat Antiinfect Drug Discov* 2010; 5: 124-151.
- [23] Brandenburg KS, Weaver AJ Jr, Karna SLR, You T, Chen P, Stryk SV, Qian LW, Pineda U, Abercrombie JJ and Leung KP. Formation of pseudomonas aeruginosa biofilms in full-thickness scald burn wounds in rats. *Sci Rep* 2019; 9: 13627.
- [24] Brandenburg KS, Weaver AJ Jr, Qian L, You T, Chen P, Karna SLR, Fourcaudot AB, Sebastian EA, Abercrombie JJ, Pineda U, Hong J, Wienandt NA and Leung KP. Development of pseudomonas aeruginosa biofilms in partial-thickness burn wounds using a sprague-dawley rat model. *J Burn Care Res* 2019; 40: 44-57.

Cerium nitrate enhances silver dressings

- [25] Gouma E, Simos Y, Verginadis I, Lykoudis E, Evangelou A and Karkabounas S. A simple procedure for estimation of total body surface area and determination of a new value of Meeh's constant in rats. *Lab Anim* 2012; 46: 40-45.
- [26] Mitchell KB, Khalil E, Brennan A, Shao H, Rabbits A, Leahy NE, Yurt RW and Gallagher JJ. New management strategy for fluid resuscitation: quantifying volume in the first 48 hours after burn injury. *J Burn Care Res* 2013; 34: 196-202.
- [27] Weaver AJ Jr, Brandenburg KS, Smith BW and Leung KP. Comparative analysis of the host response in a rat model of deep-partial and full-thickness burn wounds with pseudomonas aeruginosa infection. *Front Cell Infect Microbiol* 2019; 9: 466.
- [28] Cancio LC, Horvath EE, Barillo DJ, Kopchinski BJ, Charter KR, Montalvo AE, Buescher TN, Brengman ML, Brandt M and Holcomb JB. Burn support for operation iraqi freedom and related operations, 2003 to 2004. *J Burn Care Rehabil* 2005; 26: 151-161.
- [29] Champion HR, Bellamy RF, Roberts CP and Leppaniemi A. A profile of combat injury. *J Trauma* 2003; 54: S13-S19.
- [30] D'Arpa P and Leung KP. Toll-like receptor signaling in burn wound healing and scarring. *Adv Wound Care (New Rochelle)* 2017; 6: 330-343.
- [31] Strudwick XL and Cowin AJ. The role of the inflammatory response in burn injury. In: Bayramgürler D, editor. *Hot Topics in Burn Injuries*: IntechOpen; 2017.
- [32] Herndon DN, Barrow RE, Rutan RL, Rutan TC, Desai MH and Abston S. A comparison of conservative versus early excision. *Therapies in severely burned patients. Ann Surg* 1989; 209: 547-553.
- [33] Janzekovic Z. A new concept in the early excision and immediate grafting of burns. *J Trauma* 1970; 10: 1103-1108.
- [34] Ong YS, Samuel M and Song C. Meta-analysis of early excision of burns. *Burns* 2006; 32: 145-150.
- [35] de Gracia CG. An open study comparing topical silver sulfadiazine and topical silver sulfadiazine-cerium nitrate in the treatment of moderate and severe burns. *Burns* 2001; 27: 67-74.
- [36] Garner JP and Heppell PS. Cerium nitrate in the management of burns. *Burns* 2005; 31: 539-547.
- [37] Scheidegger D, Sparkes BG, Luscher N, Schoenenberger GA and Allgower M. Survival in major burn injuries treated by one bathing in cerium nitrate. *Burns* 1992; 18: 296-300.
- [38] Dunn K and Edwards-Jones V. The role of Acticoat with nanocrystalline silver in the management of burns. *Burns* 2004; 30 Suppl 1: S1-9.
- [39] Gee Kee E, Kimble RM, Cuttle L and Stockton K. Comparison of three different dressings for partial thickness burns in children: study protocol for a randomised controlled trial. *Trials* 2013; 14: 403.
- [40] Hegggers J, Goodheart RE, Washington J, McCoy L, Carino E, Dang T, Edgar P, Maness C and Chinkes D. Therapeutic efficacy of three silver dressings in an infected animal model. *J Burn Care Rehabil* 2005; 26: 53-56.
- [41] Karlsson M, Elmasry M, Steinvall I, Sjoberg F, Olofsson P and Thorfinn J. Superiority of silver-foam over porcine xenograft dressings for treatment of scalds in children: a prospective randomised controlled trial. *Burns* 2019; 45: 1401-1409.
- [42] Kostenko V, Lyczak J, Turner K and Martinuzzi RJ. Impact of silver-containing wound dressings on bacterial biofilm viability and susceptibility to antibiotics during prolonged treatment. *Antimicrob Agents Chemother* 2010; 54: 5120-5131.
- [43] Fox CL Jr, Monafó WW Jr, Ayvazian VH, Skinner AM, Modak S, Stanford J and Condict C. Topical chemotherapy for burns using cerium salts and silver sulfadiazine. *Surg Gynecol Obstet* 1977; 144: 668-672.
- [44] Boeckx W, Blondeel PN, Vandersteen K, De Wolf-Peeters C and Schmitz A. Effect of cerium nitrate-silver sulphadiazine on deep dermal burns: a histological hypothesis. *Burns* 1992; 18: 456-462.