

Original Article

Treatment of unstable extra-articular distal radius fractures using locked volar plating and percutaneous pinning without external fixation

Saeid Sadeghi Joni¹, Pedram Yavari², Peyman Tavakoli³, Pedram Tavoosi⁴, Ghasem Mohammadsharifi²

¹Department of Radiology, Razi Hospital, Guilan University of Medical Sciences, Rasht, Iran; ²Department of Orthopedic Surgery, School of Medicine, Isfahan University of Medical Sciences, Isfahan, Iran; ³School of Medicine, Tehran University of Medical Sciences, Tehran, Iran; ⁴Department of Civil Engineering, School of Engineering, Islamic Azad University Khorasgan (Isfahan) Branch, Isfahan, Iran

Received May 29, 2020; Accepted June 22, 2020; Epub August 15, 2020; Published August 30, 2020

Abstract: Introduction: One of the most common fractions is distal radius fracture, and various treatments have been suggested for this. The purpose of this study, is comparison of Open reduction and internal fixation by using a locked volar plating compared to percutaneous pinning by cast immobilization under the elbow in patients less than 60 years with good bone density that had unstable extra-articular distal radius fracture or UDRF. Methods: This study was clinical trial. 88 patients with closed UDRF who were referred for surgical treatment entered the study. Patients were randomized into two groups: group 1 had open reduction and internal fixation by using a locked volar plating and the other group had percutaneous pinning by cast immobilization surgeries. Amount of pain [by using Visual analog scale or VAS] and functional results of two methods were compared 3 and 12 month after surgeries. Findings: The intensity of pain was higher in the pinning group 3 and 12 month after treatment ($P=0.001$ and $P=0.390$ respectively). The range of motions in the plating group was significantly better ($P<0.001$). There was a significant difference in performing daily activities 3 month after treatment between the two groups, but a significant limitation in daily activities, observed 12 months after surgery in pinning group ($P=0.004$). Conclusion: Bone fixation, using locked volar plating, can be a better modality with regard to postsurgical pain and also the wrist range of motion than percutaneous pinning with cast immobilization in patients younger than 60 years sustaining unstable, closed extra-articular, distal radius fracture.

Keywords: Fixing fracture, radius fracture, surgery methods

Introduction

One the most common kind of fractures in orthopedic clinics is distal radius fracture [1]. type of fracture occurs in younger people after major traumas; while in older people, it's more likely to result in minor injuries [2]. As these fractures results from a wide variety of wrist injury patterns, treating them can be challenge for orthopedic surgeons.

Surgeons may prefer to use only one specific method of treatment of unstable distal radius fractures (UDRF) [3]. Fixed and immobilized by cast is one of the most common conservative methods for UDRF [4]. On the other hand, two main surgical procedures for UDRF include: close and percutaneous pinning with or without external fixation and open reduction and inter-

nal fixation (ORIF) with volar or dorsal plating [5, 6].

The biomechanical locked volar plating leads to a more significant stability than percutaneous pinning in UDRFs [7]. But fixing the fracture with locked volar plating can be associated with some complications such as tendon ruptures, plate problems, infection, fracture displacement, complex regional pain syndrome (CRPS) and also neurological disorders [8, 9]. On the other hand, percutaneous pinning can be associated with some side effects such as pin loosening, infection around the pin, malunion, stiffness of the wrist joint, decrease hand strength and damage to the superficial radial nerve [10].

Pinning through the skin and wrist casting in neutral position is a simple and effective way to

Treatments of unstable extra-articular distal radius fractures

maintain the anatomical axis of the bone after UDRFs placement, which can prevent wrist stiffness [11, 12].

To the best of our knowledge, no previous randomized clinical trials have been performed to compare the percutaneous pinning and cast fixation and volar locked plate without casting in the treatment of extra-articular UDRFs.

However, some studies have reported better outcomes and fewer side effects following the use of locked volar plating compared to the concomitant use of external fixator and percutaneous pinning in intra-articular UDRFs treatment [13, 14]. The main purpose of this study was to compare ORIF using a locked volar plating with three pins through the skin and casting under the elbow level in patients with proper bone density who had extra-articular UDRF.

Methods and materials

Study design

This study was a randomized single-blind controlled clinical trial. Overall, 88 patients aged 18 to 60 years participated in the study. Eligible patients were people with closed UDRF and extra-articular who were referred for surgical treatment. The study was conducted in Imam Khomeini educational hospital which is a level three referral center in Tehran, between February 2019 and February 2020.

Study population

Calculated using statistical formulas and according to $\alpha=0.05$, $\beta=0.2$ and expecting for at least 5 degrees difference in the range of motion between the two groups. With this input, the sample size of 44 people in each group was estimated. Eligible patients with blocked randomization sampling method were divided into two therapies group. Patients were randomized into two groups. None of the patients were aware of the purpose of the study; while the surgeons were aware, it had no detrimental effect on the results.

Inclusion and exclusion criteria

The inclusion criteria were: age between 18 to 60, signing the informed consent, fracture instability based of radiological variables includ-

ing initial Dorsal angulations greater than 20 degree, shortness more than 5 mm, significant fracture of posterior distal radius cortex, failure of closed reduction and immobility. Patients randomly divided into two groups; pinning group for which closed reduction and fixation with pin was done through the skin and plating group for which the main ORIF treatment was performed with locked volar plating. Our exclusion criteria were: open distal radius fracture, intra-articular fracture (AO type B), multiple concomitant fractures and injuries, history of distal radius fracture, history of neurological disease, rheumatoid arthritis, bone disease such as osteoporosis, metabolic bone disease such as rickets and connective tissue disease were at the same time causing problems in the healing process.

Measuring tools

Patients with closed and isolated UDRF without joint involvements entered the study within 48 hours after injury. Radiography with anterior-posterior and lateral views was taken from all patients and evaluated by a radiologist. Osteoporosis was investigated in patients being treated with corticosteroid, anticonvulsant drugs, Proton pump inhibitors (PPIs), selective serotonin reuptake inhibitors (SSRIs), medroxyprogesterone acetate, heparin and GnRH agonists. To measure bone mass, dual energy X-ray absorptiometry (DXA) was used to screen for osteoporosis in high-risk individuals. Bone minerals density was expressed as a T score and a score of <-2.5 was considered osteoporosis.

Surgical procedures

At the beginning of the study, a conscious written consent was obtained from all patients. The study protocol was approved by the ethical committee and the research board of Tehran University of Medical Science. All surgeries were performed by two experienced orthopedic surgeons under general anesthesia. 1 gram Cefazolin was injected intravenously for all patients 30 minutes before surgeries. After sterile preparation and drape, one of two surgical procedures was performed, which is described in detail below.

Closed reduction and percutaneous pinning method: in this method, the thumb and index finger were placed in the Finger traps. To stabi-

Treatments of unstable extra-articular distal radius fractures

lize two flat 1.6 mm pins were inserted into the radius bone through the styloid. Another pin entered the bone from the dorsal surface on the ulnar side of the radius bone and under fluoroscopy guidance. Then the limb from the elbow level was fixed with cast for 6 weeks. After that, the cast and pin were removed and physiotherapy was performed for all patients.

ORIF with locked volar plating was performed as following: In this procedure, a longitudinal incision was made between the brachioradialis muscle with the radial artery on the lateral side and the flexor carpal radialis muscle with the median nerve on the medial side. After reduction, the T shaped plate was directly on the bone radius distal. Plate position and no damage to the radio carpal joint were confirmed by using C-arm. Physiotherapy was performed after the first week to avoid movement restriction.

Follow up

Both groups were evaluated and examined 3 and 12 months after surgeries for response to treatment, in each examination, clinical history was taken on the ability to perform daily activities, the ability of the wrist and the range of motion. The severity of pain in each visit was also measured using visual analog scale (VAS) with a score of 1 to 10.

Daily activities were classified into three grades (exactly like before, relatively like before and reduced). Accepted radiological indexes were investigated for evaluating degenerative changes in assessments. These indexes included: joint space depletion, osteophyte (bone thorn), subcondreal sclerosis, subcondreal sclerosis cyst and loose bodies were also recorded by radiologists.

The Mayo scoring system was used each time to quantify the response to treatment and patient performance. In this system, the amount of pain, the range of motion relative to the healthy limb, the functional state, the deviation of the wrist and the strength of the fist were measured using a dynamometer by a physiotherapist. Thus, patients' scores were classified as 90-100 excellent, 80-90 good, 70-80 satisfactory and less than 70 poor. In addition, complications such as superficial infection, pin infection, sensory and motor impairment, stiffness and restriction of movement in the wrist joints, lack of bone repair, rupture of the long

thumb opening tendon and lateral displacement of broken bone, each patient was recorded in a questionnaire. According to the range of motion of the wrist joint, patients were divided into four groups.

Group 1 (excellent): Natural movement and mobility limitation less than 10 degrees, radius shortness less than 5 mm and painless.

Group 2 (good): Mobility limitation less than 20 degrees, radius shortness less than 10 mm and painless.

Group 3 (Relatively good): Movement limitation 20 to 30 degrees, Radius shortness of about 10 mm and pain following activity.

Group 4 (bad): Mobility limit more than 30 degrees, radius shortness more than one centimeter and painful.

The initial outcome of the present study was to examine the range of motion of the wrist joint after surgery, which was examined by one of the researchers, 3 and 12 months after surgery.

Secondary outcomes included radiological indicators and other functional criteria, including pain intensity and ability to perform daily activities 3 and 12 months after surgery.

Statistical analysis

According to the same studies and statistical calculations, the sample size was determined as 40 patients in each group but we also considered that some patients might exclude during the study. As a result, sample size was considered 100 patients.

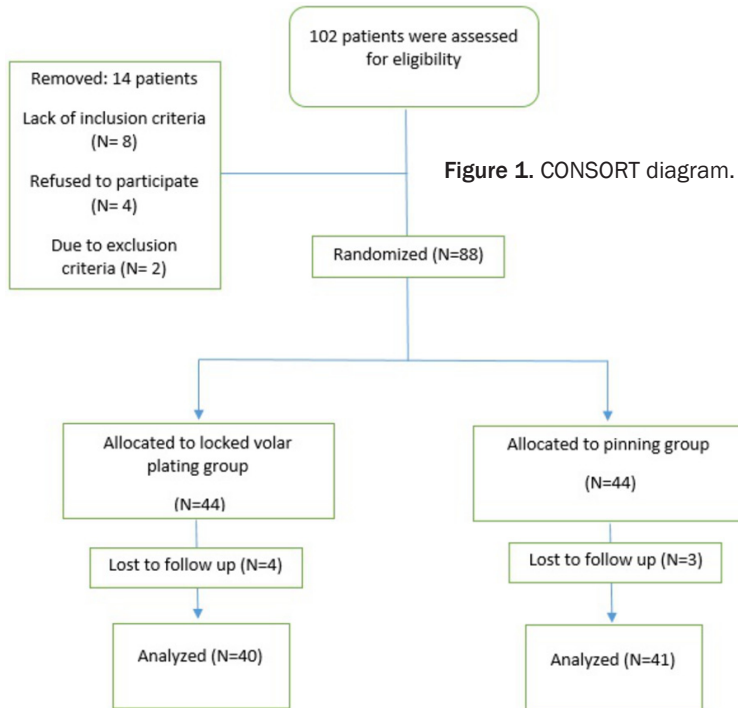
Finally, the data were analyzed in SPSS software (version X, IBM Corporation, Armonk, NY). $P < 0.05$ was considered as a significance threshold. Qualitative variables were compared using χ^2 and quantitative variables were compared using Paired T-test. Quantitative variables had a normal distribution and a standard deviation was presented.

Results

Population

In the present study, 102 patients with UDRF were examined to match the criteria for enter-

Treatments of unstable extra-articular distal radius fractures



ing the study. 88 patients were eligible and were selected.

During the study period, 7 patients were excluded from the study due to lack of cooperation for radiological follow-up and imaging (4 from the plating group and 3 from the pinning group). **Figure 1** shows the CONSORT diagram of the current study. The mean age of plating and pinning groups were 52.56 ± 18.22 and 50.80 ± 4.66 respectively, and there was no significant difference between the two groups regarding age of the patients ($P=0.530$).

Demographic data

26 women participated in the plating group and 23 women in the pinning group (65.0 and 56.1% respectively), but there was no significant difference between the groups regarding sex of patients ($P=0.500$). There was also no significant differences between two groups based on fracture mechanism ($P=0.340$). Patient's primary information are summarized in **Table 1**.

Patients' symptoms

Distribution of patients' symptoms 3 and 12 months after surgery is presented separately for both groups in **Table 2**.

Our data indicated that the intensity of pain was higher in the pinning group 3 and 12 months after treatment ($P=0.001$ and $P=0.390$ respectively). The range of flexion and joint extension in the plating group was significantly better ($P<0.001$). Examining the ability to perform daily activities 3 months after treatment did not show a significant difference between the two groups. Decreasing daily activities was observed in 15.0% of patients in the plating group and 31.7% of patients in the pinning group ($P=0.230$). However, the restriction on daily activities was significantly higher in the pinning group 12 months after surgery. There was no significant difference between the two groups regarding degenerative radiological

changes 3 months ($P=0.270$) and 12 months ($P=0.310$) after surgery. The MAYO index was used to measure patient's life's quality. The average scores in the plating and pinning group were respectively 77.28 ± 5.04 and 68.00 ± 10.24 with a significant difference between the two groups ($P<0.001$).

Radiological findings

Radiological variables are presented in **Table 3**. There was a significant difference between the average scores of all radiological variables in the two groups. Volar tilt values in the plating group were significantly higher than the pinning group in 3 and 12 months after surgery (follow up for both times $P<0.001$). According to the findings, the recovery situation in 2 people (5%) from the plating group was excellent. Also, the recovery status in 22 patients (55%) under plating and 9 patients (22%) under pinning was well reported. The recovery situation in the plating group was better than pinning group (Follow up twice for 3 and 12 months $P<0.001$). Superficial infection was observed in 2 patients in the plating group and 1 patient in the pinning group, which was treated with oral antibiotics (cephalexin at a dose of 2 g per day for 10 days) in both groups. Also, superficial radial nerve branch injury was observed in 1 patient of the

Treatments of unstable extra-articular distal radius fractures

Table 1. Demographic data of patients

Variable		Locked volar plating (N=40)	Percutaneous pinning (N=41)	P-value
Sex	Male	14 (35%)	18 (43.9%)	0.500
	Female	26 (65%)	23 (56.1%)	
Age (mean ± SD)		52.56±18.22	50.80±4.66	0.530
Fracture mechanism	Car accident	31 (77.5%)	33 (80.4%)	0.340
	Assault	3 (7.5%)	2 (5%)	
	Falling	4 (10%)	3 (7.3%)	
	Bicycle accident	2 (5%)	3 (7.3%)	

pinning group, which improved spontaneously in follow-up.

Discussion

In this randomized controlled trial, the functional and radiological results of pinning with three pins through the skin and postoperative cast immobilization with surgery and with the help of locked volar plating without cast immobilization were compared in closed UDRF and extra-articular treatment. Main finding of this study showed that the use of a locked volar plating for the treatment of closed and extra-articular UDRF was clearly better.

The locked volar plating is used as a good method of surgical fixation in UDRF. In addition, fixing fractures with percutaneous pinning is often used in many medical centers [10]. Choosing one of these two surgical procedures is almost one of the most important issues in clinical performance [15]. External fixator plays an important role in the treatment of UDRF [14]. It also helps stabilize fractures and supports radius bone alignment, but its use can be associated with minor side effects that have been identified in some previous studies, including displacement, infection of the pin system and neuropathy of the median and radial nerves. The research results showed that closed placement method and cast immobilization without percutaneous pinning did not have a satisfactory result in aligning the radius bone length. In a study by Das and colleagues in 2011, they examined the use of percutaneous pinning and immobilization through plastering cast in 32 patients in the age range of 18 to 70 years with extra-articular radial distal fracture [16]. Their research showed that in 65.6% of patients, the fracture healed with a very good reconstruction of the anatomical structure. Therefore, there is a difference of opinion in the use of external fixator or cast immobilization

after percutaneous pinning that present study used the plastering cast method [17]. The results of wrist function are one of the most important factors in evaluating the benefits of using a surgical procedure [18]. The range of motion in the wrist joint is commonly used to determine joint function after surgery [19].

In two previous clinical trials, a wide range of hand movements and strengths were observed and there was a significant difference between the use of locked volar plating compared to percutaneous pinning and external fixator in the treatment of internal and external joint distal radius fracture [20, 21]. McFadyen and others in a randomized clinical trial, compared the effectiveness of a locked volar plating with implantation three pin through the skin in patients with unilateral closed and extra-articular UDRF. They used elbow cast immobilization in two ways for 6 weeks after surgery; however, in the present study, only in patients under percutaneous pinning, immobilization was performed with cast. In fact, they eliminated the positive effects of external fixator and cast immobilization. McFadyen and others also used two types of plates; however, only one type of plate was used in the present study [22].

They followed up the patients for 6 month after surgery and used Gartland, Werley, Disabilities of the Arm and Shoulder and Hand (DASH) scores to evaluate functional results that wrist function in plating group was significantly better than the pinning group 3 and 6 months after the surgery. The results of their study showed that immediate postoperative reduction of the pin was better than plate reduction. The results of the study by Perugia and others in 2014 showed that the use of locked volar plating completely improves range of motion in patients with unilateral closed and extra-articular UDRF [23]. In the present study, the range of motion

Treatments of unstable extra-articular distal radius fractures

Table 2. Clinical symptoms 3 and 12 months after surgery

Variable	3 months after surgery			12 months after surgery			
	Pinning group	Plating group	P-value	Pinning group	Plating group	P-value	
Pain (based on VAS) (mean ± SD)	2.6±1.1	2.5±1.0	0.001	1.1±0.7	0.9±0.5	0.001	
Wrist extension (degree) (mean ± SD)	51.0±6.0	42.0±7.1	>0.001	53.0±7.0	48.0±7.3	>0.001	
Wrist flexion (degree) (mean ± SD)	62.0±5.0	50.0±10.0	>0.001	62.0±5.6	55.0±7.7	>0.001	
Ability of performing daily activities (number (%))	Completely same as before fracture	16 (40)	14 (34)	0.30	18 (45)	5 (12)	0.002
	Almost same as before fracture	18 (45)	14 (34)		17 (43)	26 (64)	
	Reduced	6 (15)	13 (32)		5 (12)	10 (24)	

Table 3. Radiological indexes 3 and 12 months after surgery

Variable	3 months after surgery			12 months after surgery			
	Pinning group	Plating group	P-value	Pinning group	Plating group	P-value	
Volar angle (mean ± SD)	5.6±4.3	2.2±0.5	>0.001	3.5±2.2	6.2±5.0	0.001	
Radial shortage (degree) (mean ± SD)	3.8±2.2	5.7±2.4	>0.001	5.1±2.7	3.3±2.2	0.001	
Ulnar variance (degree) (mean ± SD)	3.3±1.7	3.8±1.5	0.172	2.5±1.9	2.3±1.5	0.340	
Deviation to radial side (degree) (mean ± SD)	10.0±3.5	7.4±3.0	0.001	8.2±3.5	12.1±4.0	>0.001	
Degenerative changes (number (%))	Yes	36 (90)	33 (83)	0.30	37 (93)	33 (83)	0.680
	No	4 (10)	7 (17)		3 (7)	7 (17)	

was evaluated and it was shown that the range of flexion and extension for the wrist was significantly better after embedded locked volar plating. Also, the wrist deviation was evaluated but the abduction and extension were not measured in the Mayo scoring system. Proper wrist function, wrist activity, acceptable improvement in radiography and complications are important factors in choosing a surgical procedure to treat UDRF [21]. Mayo scoring system is an important tool for evaluating the outcome of joint performance [24]. Gaining power is responsible for 25% of the total score on Mayo wrist scores and is a dominant predictor of joint performance. There is a direct connection between the final results and the measured anatomical reduction using radiographic indicators [25]. Lack of anatomical reduction leads to deformity, weakness and pain in the wrist, while locked volar plating provides strength and stability to the structure and helps to improve the movement of the wrist earlier [26, 27]. Most previous studies have cited ulnar variance, radial inclination, intra-articular dislocation or step and intra-articular gap as radiographic indicators [28, 29]. The relationship between this radiographic restoration and improved range of motion is important in previous studies. Among radiographic indicators, restoring ulnar variance and volar tilt is essential for good UDRF performance [30]. Ulnar variance and volar tilt significantly improved after embedded locked volar plating to treat radial and intra-articular fractures of the distal radius [30]. However, the results of some studies show that the return to wrist activity is more followed by closed reduction and fixation with the pin. In the present study, a comparison of ulnar variance showed that the use of locked volar plating was not preferable to percutaneous pinning.

Overall, functional results and radiographic indicators appear to be acceptable in both methods. Various studies of postoperative complications have evaluated these two methods. Most previous studies reported lower rates of complications in the locked volar plating method. The most common complication is postoperative pain, which has been less commonly observed in some studies in locked volar plating.

Conclusion

In the present study, the incidence of complications in the two groups was not significantly dif-

ferent. Based on follow-up of 3 and 12 months after surgery, we believe that the ORIF method, including locked volar plating, is a suitable method in patients under 60 years of age with UDRF. However, the results of pinning are also acceptable.

Disclosure of conflict of interest

None.

Address correspondence to: Ghasem Mohammadsharifi, Department of Orthopedic Surgery, School of Medicine, Isfahan University of Medical Sciences, Hezar Jarib St., Isfahan 6516675349, Isfahan Province, Iran. Tel: +989133236863; E-mail: iman.m.sharifi@gmail.com

References

- [1] Makhni MC, Makhni EC, Swart EF and Day CS. Distal radius fracture. In: editors. *Orthopedic Emergencies*. Springer; 2017. pp. 443-446.
- [2] MacIntyre NJ and Dewan N. Epidemiology of distal radius fractures and factors predicting risk and prognosis. *J Hand Ther* 2016; 29: 136-45.
- [3] Hamada Y, Gotani H, Hibino N, Tanaka Y, Satoh R, Sasaki K and Kanchanathepsak T. Surgical strategy and techniques for low-profile dorsal plating in treating dorsally displaced unstable distal radius fractures. *J Wrist Surg* 2017; 6: 163-169.
- [4] Saving J, Ponzer S, Enocson A and Navarro CM. Distal radius fractures-regional variation in treatment regimens. *PLoS One* 2018; 13: e0207702.
- [5] Lewallen LW and Rizzo M. External fixation and percutaneous pinning for distal radius fractures. In: editors. *Distal Radius Fractures*. Springer; 2016. pp. 151-163.
- [6] Yuan Z, Yang Z, Liu Q and Liu Y. Complications following open reduction and internal fixation versus external fixation in treating unstable distal radius fractures: grading the evidence through a meta-analysis. *Orthop Traumatol Surg Res* 2018; 104: 95-103.
- [7] Ramavath A, Howard N and Lipscombe S. Biomechanical considerations for strategies to improve outcomes following volar plating of distal radius fractures. *J Orthop* 2019; 16: 445-450.
- [8] Thorninger R, Madsen ML, Wæver D, Borris LC and Rölfing JHD. Complications of volar locking plating of distal radius fractures in 576 patients with 3.2 years follow-up. *Injury* 2017; 48: 1104-1109.
- [9] Alter TH, Sandrowski K, Gallant G, Kwok M and Ilyas AM. Complications of volar plating of dis-

Treatments of unstable extra-articular distal radius fractures

- tal radius fractures: a systematic review. *J Wrist Surg* 2019; 8: 255-262.
- [10] Peng F, Liu Y and Wan Z. Percutaneous pinning versus volar locking plate internal fixation for unstable distal radius fractures: a meta-analysis. *J Hand Surg Eur Vol* 2018; 43: 158-167.
- [11] Zhu A, Thomas J and Lawton JN. Distal radius fracture: Kapandji (Intrafocal) pinning technique. In: editors. *Distal Radius Fractures*. Springer; 2016. pp. 121-134.
- [12] Chen ACY, Chou YC and Cheng CY. Distal radius fractures: minimally invasive plate osteosynthesis with dorsal bicolunar locking plates fixation. *Indian J Orthop* 2017; 51: 93-98.
- [13] Sharma A, Pathak S, Sandhu H, Bagtharia P, Kumar N, Bajwa RS, Pruthi V and Chawla JS. Prospective randomized study comparing the external fixator and volar locking plate in intraarticular distal radius fractures: which is better? *Cureus* 2020; 12: e6849.
- [14] Saving J, Enocson A, Ponzer S and Navarro CM. External fixation versus volar locking plate for unstable dorsally displaced distal radius fractures-a 3-year follow-up of a randomized controlled study. *J Hand Surg Am* 2019; 44: 18-26.
- [15] Kara A, Ertürer E, Seçkin F, Akman Ş and Öztürk İ. The treatment method and results of percutaneous pinning and dynamic external fixator application for unstable distal radius fractures. *Sisli Etfal Hastan Tip Bul* 2018; 52: 173-178.
- [16] Das AK, Sundaram N, Prasad TG and Thanavelu SK. Percutaneous pinning for non-comminuted extra-articular fractures of distal radius. *Indian J Orthop* 2011; 45: 422-6.
- [17] Rizzo M, Katt BA and Carothers JT. Comparison of locked volar plating versus pinning and external fixation in the treatment of unstable intraarticular distal radius fractures. *Hand* 2008; 3: 111-117.
- [18] Wolff AL, Patel Y, Zusstone E and Wolfe SW. Self-identified functional limitations improve in patients with degenerative wrist arthritis after surgery. *J Hand Ther* 2019; [Epub ahead of print].
- [19] Carpenter C and Amirfeyz R. Complications of hand surgery. *Orthopaedics and Trauma* 2019; 33: 360-364.
- [20] Grewal R, MacDermid JC, King GJ and Faber KJ. Open reduction internal fixation versus percutaneous pinning with external fixation of distal radius fractures: a prospective, randomized clinical trial. *J Hand Surg Am* 2011; 36: 1899-906.
- [21] Karantana A, Downing ND, Forward DP, Hatton M, Taylor AM, Scammell BE, Moran CG and Davis TR. Surgical treatment of distal radial fractures with a volar locking plate versus conventional percutaneous methods: a randomized controlled trial. *JBJS* 2013; 95: 1737-1744.
- [22] McFadyen I, Field J, McCann P, Ward J, Nicol S and Curwen C. Should unstable extra-articular distal radial fractures be treated with fixed-angle volar-locked plates or percutaneous Kirschner wires? A prospective randomised controlled trial. *Injury* 2011; 42: 162-166.
- [23] Perugia D, Guzzini M, Civitenga C, Guidi M, Dominedò C, Fontana D and Ferretti A. Is it really necessary to restore radial anatomic parameters after distal radius fractures? *Injury* 2014; 45: S21-S26.
- [24] Souer JS, Lozano-Calderon SA and Ring D. Predictors of wrist function and health status after operative treatment of fractures of the distal radius. *J Hand Surg Am* 2008; 33: 157-163.
- [25] Sommer C, Nork SE, Graves M, Blauth M, Rudin M and Stoffel K. Quality of fracture reduction assessed by radiological parameters and its influence on functional results in patients with pilon fractures-a prospective multicentre study. *Injury* 2017; 48: 2853-2863.
- [26] Launay F and Pesenti S. Forearm lengthening: management of elbow and wrist. *J Child Orthop* 2016; 10: 593-595.
- [27] Isobe F, Yamazaki H, Hayashi M, Uchiyama S, Miyaoka S and Kato H. Prospective evaluation of median nerve dysfunctions in patients with a distal radius fracture treated with volar locking plating. *J Hand Surg Asian Pac Vol* 2019; 24: 392-399.
- [28] Ozer K, Zhu AF, Siljander B, Lawton JN and Waljee JF. The effect of axial loading on ulnar variance. *J Wrist Surg* 2018; 7: 247-252.
- [29] Bessho Y, Nakamura T, Nishiwaki M, Nagura T, Matsumoto M, Nakamura M and Sato K. Effect of decrease in radial inclination of distal radius fractures on distal radioulnar joint stability: a biomechanical study. *J Hand Surg Eur Vol* 2018; 43: 967-973.
- [30] Taylor KF, Gendelberg D, Lustik MB and Drake ML. Restoring volar tilt in AO type C2 fractures of the distal radius with unilateral external fixation. *J Hand Surg Am* 2017; 42: 511-516.