

## Original Article

# Osteosynthesis of pediatric femoral shaft fractures with flexible intramedullary nailing-experience from developing world

Tabish Tahir Kirmani, Najmul Huda, Gaurav Mishra

*Department of Orthopedics, Teerthanker Mahaveer Medical College and Research Center, Moradabad 244001, Uttar Pradesh, India*

Received June 18, 2020; Accepted August 14, 2020; Epub August 15, 2020; Published August 30, 2020

**Abstract:** Background: Flexible intramedullary nailing (FIN) has become the standard treatment for pediatric femoral fractures in the 6-14 years age group. The other treatment options include traction plus spica casting and external fixation. In spite of excellent results described, there is disunity in the orthopedic fraternity regarding its usefulness and nail material. The aim of our study is to determine the outcome of pediatric femur fractures treated with Stainless steel FIN. Methodology: Between 2014 to 2018, 45 children within the age group of 6-12 years with femoral shaft fractures were included in the study. Two Stainless steel nails of predetermined size were inserted in a retrograde fashion under fluoroscopy. Patients were followed up at regular intervals to assess clinical and radiological parameters. Final results were evaluated using Flynn's clinical criteria. Results: There were 29 boys and 16 girls with an average age of 10.2 years. Fracture patterns included transverse (n=8), oblique (n=20), spiral (n=12) and comminuted (n=5). Open injuries were present in two cases and five patients had associated injuries. The mean injury to surgery interval was 2.9 days, mean hospital stay was 4.8 days and mean time to union was nine weeks. Complications included deep infection with delayed union in one case, superficial infection in two cases, malunion in three cases, limb length discrepancy of >10 mm in one patient and skin irritation from prominent nail tips in five patients. Results were excellent in 36 patients, satisfactory in eight patients and poor in one patient. Conclusion: FIN is safe, reliable and efficacious method of fixation because of its simplicity, minimal invasiveness, ease of insertion and removal with better cosmesis, rapid union with short rehabilitation, less psychosocial stress to the patient and family.

**Keywords:** Pediatric femur fractures, flexible intramedullary nailing, complications, Flynn's criteria

## Introduction

Fractures of the femoral shaft are common in children, representing about 2% of all bony injuries [1]. These injuries require hospitalization, creating considerable short term disability with physical and psychological stress to both the patient and the family [2]. The majority of these fractures in older children are caused by high energy trauma such as motor vehicle accidents and significant falls [3]. The treatment of these injuries depends mainly on the age, fracture location and pattern and whether the fracture is closed or open. There is little altercation regarding the treatment method in children less than five years or more than 15 years old. Fractures in children less than five years are treated with skin traction followed by casting or early spica casting with good results [4]. Fractures in patients more

than 15 years old are treated with interlocking intramedullary nail as in adults [5]. Children in the age group of 6-14 years have various treatment options including traction followed by casting, retrograde Flexible intramedullary nailing (FIN), submuscular plating and external fixation with no clear uniformity in the literature [6-8].

More fractures in this age group are now treated operatively rather than conservatively. Non-operative treatment with traction and casting results in prolonged bed rest, psychosocial disruption, increased hospital stay, knee stiffness, malunion and plaster complications [4, 6]. The benefits of operative treatment are proper reduction, stable fixation, rapid mobilization, decreased hospital stay, less disruption of social life, early return to school and can be used in patients with open fractures, multiple

injuries, head trauma, floating knees [9-12]. External fixation, mainly used in open injuries are associated with complications of pin tract infection, knee stiffness and refracture following removal of fixator [7, 13]. The use of rigid antegrade intramedullary nail risks the development of avascular necrosis of femoral head, growth arrest of greater trochanter with secondary coxa valga and thinning of femoral neck [5, 14].

Elastic or flexible retrograde intramedullary nails (FIN) are now preferred for treating femoral fractures in age group of 6-14 years. Initially introduced by Nancy group in 1979 [9], several authors have reported favorable results with FIN [11, 12, 15]. FIN acts as a load sharing internal splint providing relative stability for callus formation, maintains alignment and length of bone and permits rapid mobilization of adjacent joints [16]. It is a minimally invasive procedure with easy insertion and removal, no risk of physeal damage or refracture and is cosmetically appealing. Both titanium and stainless steel nails can be used with advantages of each over other. Stainless steel nails are much cheaper than titanium nails and have been associated with lower rate of complications than titanium nails [17]. We used cheaper stainless steel nails as vast majority of patients visiting our trauma center are poverty stricken. We conducted a prospective study to assess the clinico-radiological outcome and complications of pediatric femoral shaft fractures treated with Flexible intramedullary nailing in 6-12 years age group.

### Materials and methods

The prospective hospital based study was conducted in our department from 2014 to 2018 after obtaining ethical clearance from the College Research committee. Proper informed consent was taken from all the children's guardians for participating in the study. A total of 49 cases of femoral shaft fractures in the age group of 6-12 were enrolled in the study out of which four patients were lost to follow-up and 45 were available at final follow-up.

#### *Inclusion criteria*

All closed fractures and Gustillo Anderson Open type I injuries were included.

#### *Exclusion criteria*

Pathological fractures, Gustillo Anderson type II and III Open injuries, grossly comminuted

fractures (Winqvist Hansen type IV), and fractures in patients with neuromuscular weakness or metabolic bone diseases.

#### *Preoperative preparation*

After admitting the patients, detailed history was taken with emphasis on age and sex, mode of injury, duration of trauma and associated injuries. The limb was examined for swelling, any wound, bruising and neurovascular status. Radiographs were ordered and evaluated for fracture type, location, comminution (Winqvist Hansen classification) and width of isthmus. Fixed traction was applied for pain relief and all necessary preoperative investigations were done. Patients were operated as early as possible. The nail diameter to be used was calculated based on Flynn's formula (Nail diameter =  $0.4 \times$  width of isthmus) [11]. Statistical analysis was carried out using SPSS software version 17.0 (SPSS Inc., Chicago, Illinois, USA). Student's t-test was used to examine the differences between groups. All data between two groups were compared using  $\chi^2$ -test analysis. Statistical significance was set at  $p$  value  $< .05$ .

#### *Surgical technique*

Patients were operated under spinal/general anesthesia on a fracture table after administering prophylactic antibiotic. A small skin incision was given and entry made with an awl in distal metaphysis two cm above the distal femoral physis, both medially and laterally. Nails of precalculated size were slightly bend gently so that apex lies at level of fracture site. Both the nails were advanced to fracture site, the fracture was reduced and nails were passed into the proximal fragment in a C configuration. The nails were advanced to level of greater trochanter laterally and femoral neck medially. If the fracture was not reduced by closed means, mini open reduction was done in a few cases. In Open fractures, the wound was debrided, lavaged with saline and fractures were reduced. Distally the nails were cut and bend so that about 1.5 cm remains outside the bone. In the latter cases, we did not bend the nail tip but kept them flush with the metaphyseal bone. The whole procedure was done under fluoroscopic control.

#### *Postoperative protocol and follow-up*

Patients were taught quadriceps exercises from day one and toe touch assisted weight

## FIN in pediatric femur fractures

**Table 1.** Flynn's clinical criteria [11] for functional evaluation at final follow-up

Variables	Excellent result (n=36, 80%)	Satisfactory result (n=8, 17.8%)	Poor result (n=1, 2.2%)
Leg length inequality	<1.0 cm	<2.0 cm	>2.0 cm
Malalignment	5 degrees	10 degrees	>10 degrees
Pain	Nil	Nil	Present
Complication	Nil	Minor and resolved	Major complication and/or lasting morbidity

**Table 2.** Anthony Radiological criteria [18] for grading the progression of fracture union

Grading	Description
Grade 0	No identifiable fracture healing (n=0)
Grade 1	Primary bone healing with little or no periosteal new bone formation (n=0)
Grade 2	Periosteal new bone formation on two sides of femur (n=0)
Grade 3	Periosteal new bone formation on three or four sides of femur (n=45, 100%)

**Table 3.** Demographic details of patients in our study

Patient Variable	Results (n=number, percentage)
Gender	Males (n=29, 64.4%) Females (n=16, 35.6%)
Side involved	Right (n=20, 44.4%) Left (n=25, 55.6%)
Cause of injury	Motor vehicle accidents (n=31, 68.9%) Fall from height (n=11, 24.4%) Sports (n=3, 6.7%)
Fracture location	Proximal (n=7, 15.6%) Middle (n=28, 62.2%) Distal (n=10, 22.2%)
Fracture pattern	Transverse (n=8, 17.8%) Oblique (n=20, 44.4%) Spiral (n=12, 26.1%) Comminuted (n=5, 11.7%)
Winquist and Hansen (type)	I (n=24, 53.3%) II (n=16, 35.6%) III (n=5, 11.1%) IV (n=0)
Gustillo Anderson (type)	I (n=2) II (n=0) III (n=0)

bearing was allowed from second postoperative day (excluding patients with head injury and associated fractures). In patients with comminuted fractures, non-weight bearing mobilization was started with the help of thigh braces. Antibiotics were continued for three days and patients were discharged mostly on second postoperative day. Postoperative radiographs were evaluated for quality of reduction, implant position, any sagittal coronal or

rotational malalignment. Clinically patients were evaluated for limb length discrepancy, limb rotation and alignment, knee motion and nail tip irritation at each follow-up. Patients were followed up at two and four weeks, two; three and six months and final follow-up at 1 year. Patients were allowed to bear weight progressively depending upon callus formation and fracture site tenderness. At the end of six months and one year, patients were evaluated with Flynn's clinical criteria (**Table 1**) and Anthony radiological criteria (**Table 2**) [11, 18].

### Results

#### Patient demographics

There were 29 boys (64.4%) and 16 girls (35.6%) in our series with an average age of 10.2 years (range 6-12). Most of the patients were in the age group of 9-12 years (n=25, 55.6%). Fractures were predominant on left side (n=25, 55.6%) than on the right side (n=20, 44.4%). The average weight of patients was 28.5 kg with a range of 19-46 kgs. The mechanism of injury included motor vehicle accidents (n=31, 68.9%), fall from height (n=11, 24.4%) and sports activities (n=3, 6.7%) (**Table 3**). Five patients had associated injuries including head injury in three patients, ipsilateral fracture both bone forearm in two cases and clavicle fracture in one case.

## FIN in pediatric femur fractures

### *Fracture characteristics*

Most of the fractures were located in the diaphysis (n=28, 62.2%), followed by distal (n=10, 22.2%) and proximal shaft (n=7, 15.6%). Fracture patterns were transverse (n=8, 17.8%), oblique (n=20, 44.4%), spiral (n=12, 26.7%) and comminuted (n=5, 11.1%). Winquist and Hansen's classification was used to classify fractures and included type I (n=24, 53.3%), type II (n=16, 35.6%), type III (n=5, 11.1%). Fracture description according to AO classification included 32 A1 (n=10, 22.2%), 32 A2 (n=16, 35.6%), 32 A3 (n=8, 17.8%), 32 B (n=11, 24.4%). There were two cases (4.5%) of Open injuries type I. The most common stainless steel nail size used was 3.5 mm in 28 patients (62.2%), 3 mm in 14 patients (31.1%) and 2.5 mm in 3 patients (6.7%).

The mean time from injury to surgery was 2.9 days (range 1-9 days). Patients with head injury were operated in the second week after injury. The mean duration of surgery was 50 minutes (range 35-75 minutes). The average hospital stay was 4.8 days (range of 3-14 days) with head injury patients having a longer stay upto two weeks. Two patients with closed fractures having soft tissue interposition required mini open reduction. In two patients with open injuries the wound was thoroughly lavaged and debrided, among which one patient developed deep infection.

### *Follow-up*

Most of patients (n=38, 84.4%) started toe touch weight bearing mobilization on second or third postoperative day, except patients with head injury (n=3) and deep infection (n=1), where delayed mobilization at two weeks was commenced. Mobilization was progressed to partial weight bearing on initial appearance of callus at fracture site usually at four weeks (range of 3-12 weeks) and to full weight bearing with presence of union at fracture site at an average of nine weeks (range of 7-22 weeks). Patients with ipsilateral upper limb fractures (n=3) were mobilized at 4-6 weeks depending upon healing of upper limb fractures. Union was defined when patient had no pain and tenderness with Grade III callus present on radiographs (Anthony *et al* criteria). Patients were instructed to bear full weight on seeing clinical and radiological union. All the patients were followed up for minimum of 12

months and a maximum of 48 months with an average follow-up of 16 months.

### *Final results*

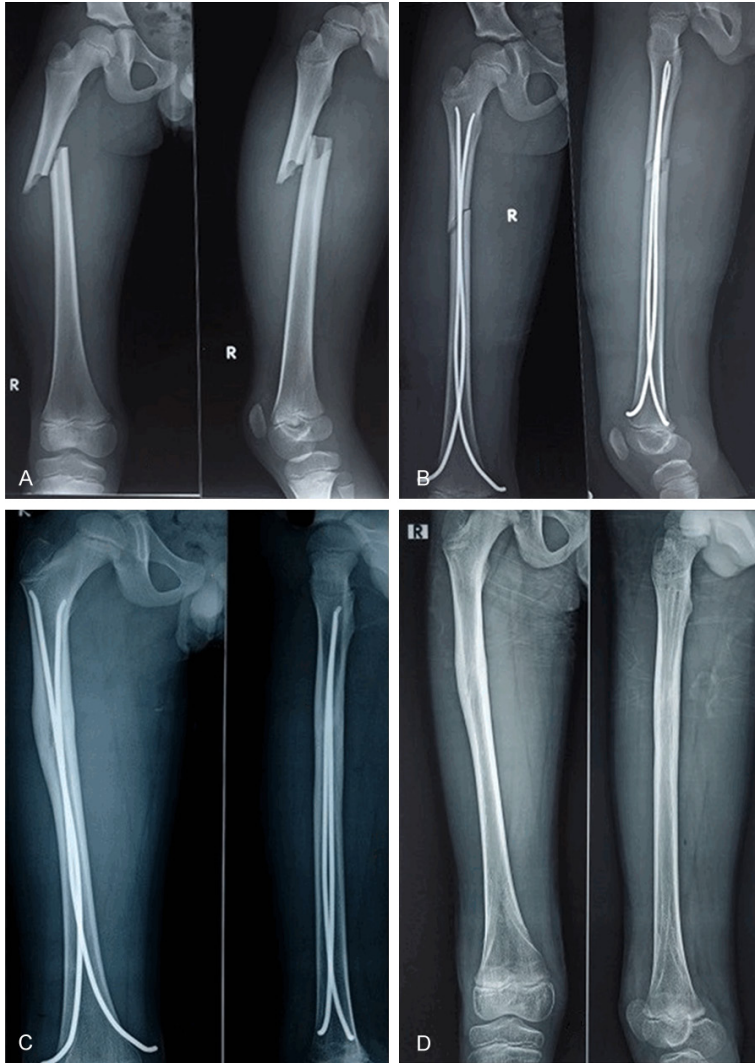
Functional evaluation was done using Flynn's criteria. Results were excellent in 36 patients (80%), satisfactory in 8 patients (17.8%) and poor in 1 patient (2.2%) (**Figures 1A-D, 2A-C, 3A-C**).

### *Complications*

In our series of 45 patients, deep infection occurred in one patient (2.2%) with type I Open fracture. Thorough wound debridement was done on day three, but nails were retained. Antibiotics (2 weeks intravenous and 4 weeks oral) were continued for six weeks and infection subsided. Radiographs at 10 weeks showed diffuse periosteal reaction, osteopenia and slight callus formation. Fracture united at 22 weeks showing delayed union (**Figure 4A-C**). The same infected patient developed knee stiffness which did not improve with continuous passive motion exercises. At eight months, after substantiating fracture union, knee manipulation under anesthesia coupled with removal of nails was done as the prominent nail tips were hampering his knee motion. At final follow-up, his knee motion was comparable to opposite side. Superficial infection at incision site occurred in two cases (4.4%), which resolved with dressings and oral antibiotics (**Table 4**).

Skin and soft tissue irritation due to prominent nail tip with overlying bursa formation occurred in five patients (11.1%). It subsided with early removal of nails in the first year itself, after establishing fracture union. Observing this, nails were slightly bend and kept flush with metaphyseal bone which negated this complication in other cases. In one case the nail tip penetrated the skin migrating distally; it was treated by cutting the nail further and burying its end within the soft tissues (**Figure 5**). Limb shortening of less than 10 mm was present in 3 cases, all in comminuted fractures. The infected patient had shortening of 18 mm at final follow-up, which was treated by shoe raise.

Malunion in coronal, sagittal and transverse planes were uncommon. Two patients had varus malunion of <10° and one patient had external rotational malalignment of 10° (6.7%)



**Figure 1.** (A) Preoperative Anteroposterior (AP) and lateral radiograph of femur showing fracture of proximal femoral shaft. (B) Postoperative AP and lateral radiographs showing fixation with FIN and excellent alignment. (C) AP and lateral radiographs at 1 year follow-up showing united fracture and after removal of nails (D).

(Figure 6A-C). The deformities were not apparent clinically but were seen on radiographs.

At final follow-up, patients were counselled for nail removal after confirming solid union. Nails were removed in 38 patients till date. No complications whatsoever were observed in extracting the nails or thereafter.

**Discussion**

Over the past two decades, pediatric femoral shaft fractures are treated operatively in patients older than six years because of reduced hospitalization and immobilization, shorter

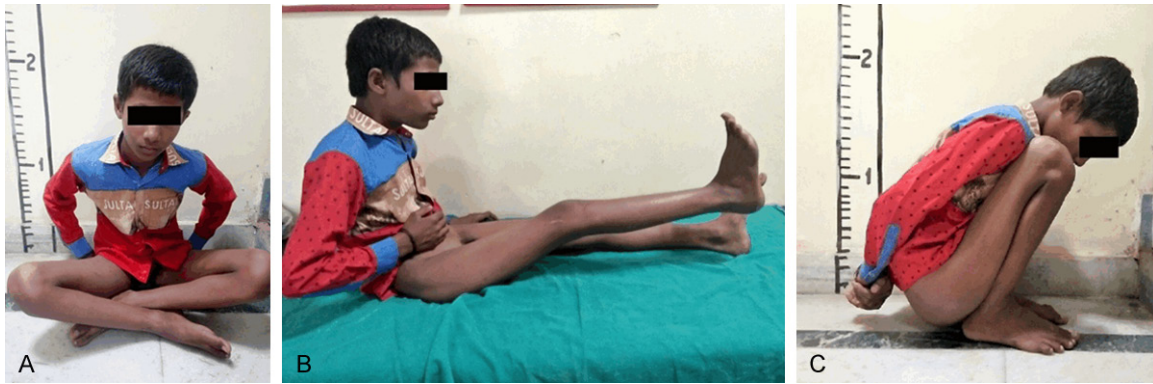rehabilitation period, less psychological impact to child [19]. Studies comparing operative versus conservative treatment method reflects the trend towards operative management of these fractures [20, 21]. Flexible intramedullary nail (FIN) has emerged to be the implant of choice for treating these fractures. It works on the principle of three point fixation providing axial, translational, rotational stability at fracture site. It has a short learning curve with minimal complications when performed properly. There is abundant callus formation, early union due to nails permitting micromotion at fracture site and no disruption of fracture hematoma [22].

Ligier JN *et al* at Nancy Hospitals first reported the outcome of FIN in 123 pediatric femur fractures [9]. They had one case of bone infection treated by drainage and removal of nail. No patient had limp or gait abnormality at final follow-up. They calculated the cost reduction of over 70% by using this technique compared to conservative treatment. In various other series using FIN, infection has been uncommon [11, 12, 15]. We had

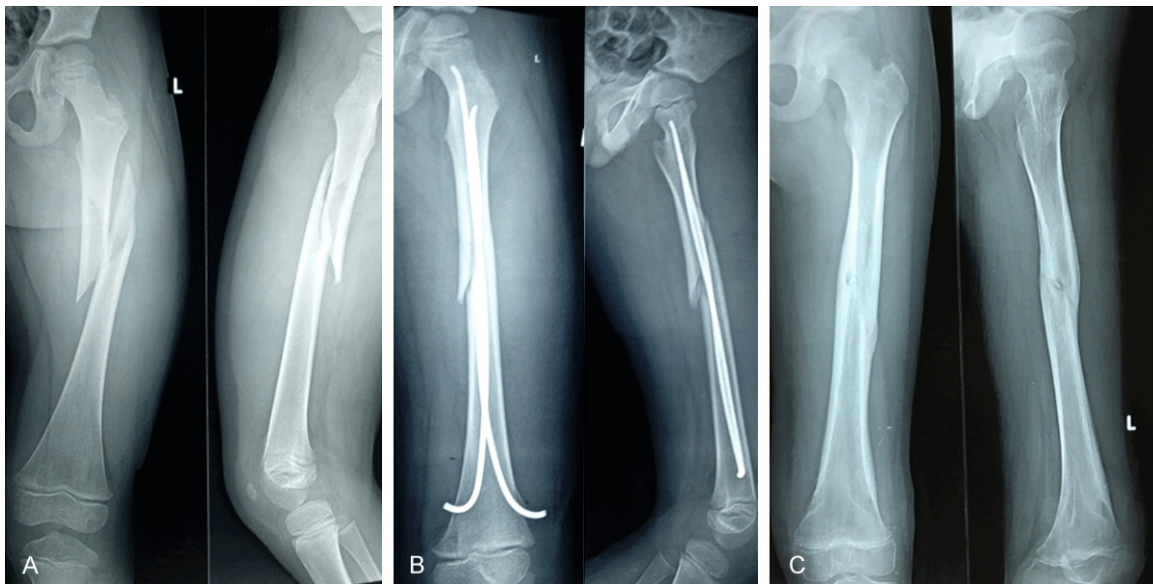
one case of deep infection in type I Open fracture which was managed by debridement and intravenous antibiotics without nail removal. Although we thoroughly debrided and washed the wound at time of fracture fixation, contamination of wound or unsterile surgical technique might have contributed to development of infection in our patient. In Open fractures with contamination, external fixation should be preferred over FIN to minimize complications.

The most common complication associated with FIN is skin irritation at entry site due to prominent nail tips. Ligier JN *et al* reported 10% incidence of skin ulcerations secondary

## FIN in pediatric femur fractures



**Figure 2.** Clinical photographs of same patient with sitting cross leg, squatting and straight leg raise-(A-C).

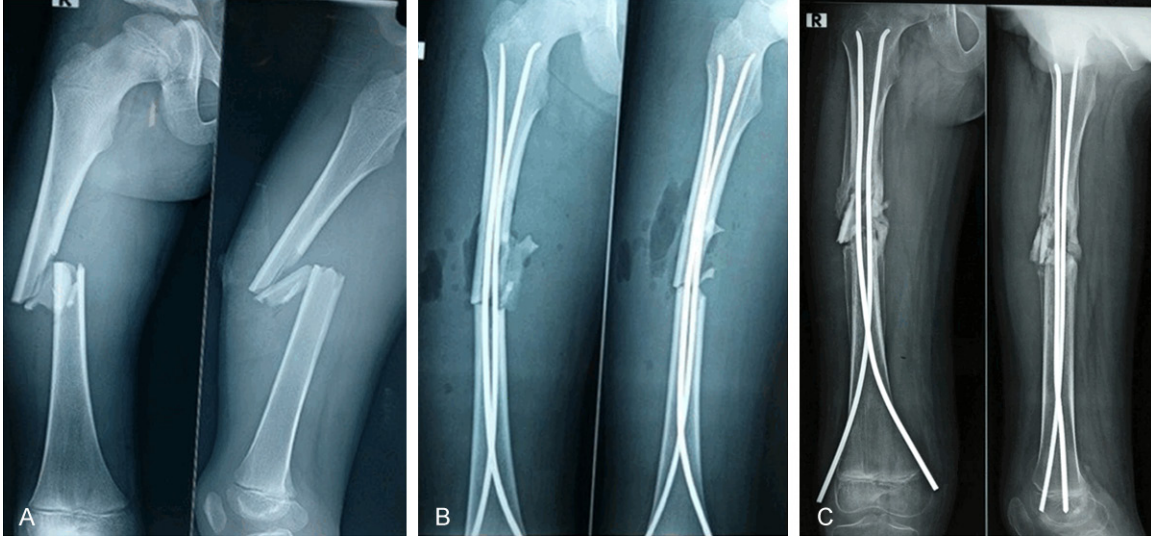


**Figure 3.** A. Preoperative AP and lateral radiograph of femur showing mid diaphysis spiral fracture. B. Postoperative AP and lateral radiographs showing fixation with FIN. C. AP and lateral radiographs after removal of implant.

to prominent nail tip, settled by trimming the nails, while Salonen *A et al* in his series of 32 patients had five cases of skin irritation at entry site [9, 23]. They attributed this for not bending nail ends towards the side of femur. Flynn's series had four cases of skin irritation after bending the nail tip away from bone for easy removal [11]. Narayanan *et al* advocated the nail tip should be kept flush with metaphyseal flare without bending (about 10 mm) to prevent this complication after noticing it in 41 out of 79 patients in his series [24]. Our series had five cases of similar symptoms with pain and bursa formation around distal nail tip with problems in knee motion. They were seen more in patients in whom the nail

tip was acutely bend. After we kept nails tip flush with metaphyseal bone, this complication was rarely seen but in one patient, with progressive weight bearing the nail migrated distally and perforated the skin resulting in exposed nail tip. We trimmed the nails later under local anesthesia. The literature is still confusing whether the nails should be bent or kept flush with metaphyseal bone. However we agree with Narayanan *et al*, that nail tip should be kept flush with metaphyseal flare without bending to avoid skin irritation.

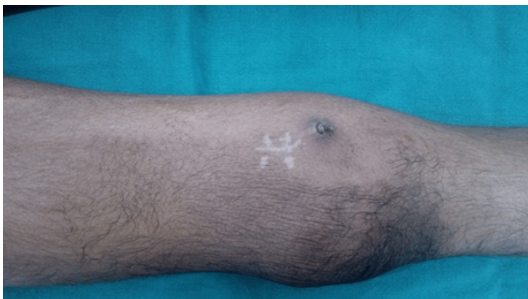Reeves *et al* did comparative study between conservative and operative methods of treatment for pediatric femur shaft fractures and



**Figure 4.** A. Preoperative AP and lateral radiographs of femur showing diaphyseal fracture. The patient had Open type II injury. B. Postoperative AP and lateral radiographs at day 3 showing abscess shadows. C. AP and lateral radiographs at 12 weeks showing delayed union with periosteal reaction, osteopenia.

**Table 4.** Various complications of our study

Complications	Descriptions
Major complications (2.2%)	Deep infection (n=1)
Minor complications (31.1%)	Nail tip skin irritation (n=5)
	Superficial infection (n=2)
	Malunion: Varus (n=2)
	Rotational (n=1)
	Limb length inequality: <1 cm (n=3)
	>1 cm (n=1)



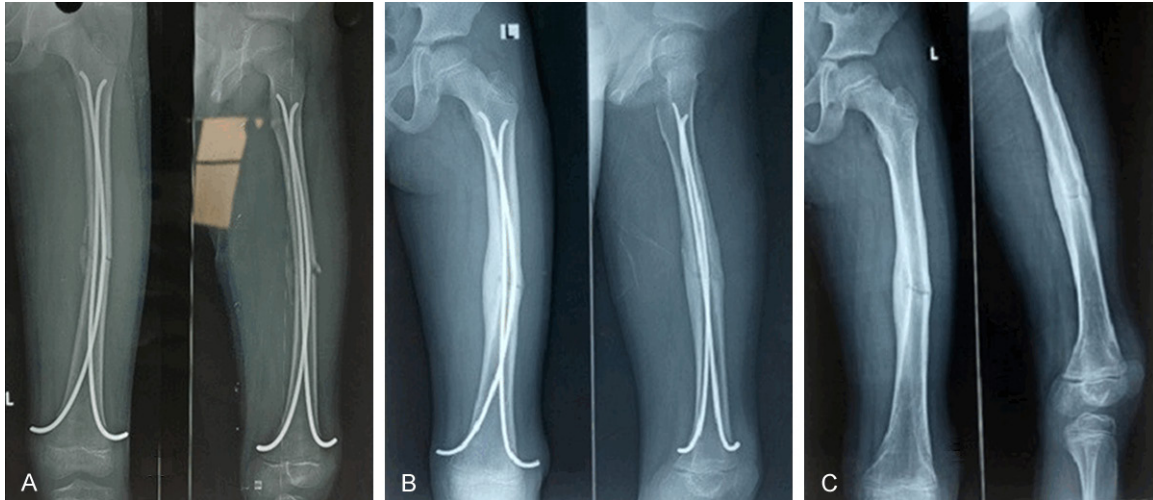
**Figure 5.** Clinical photograph showing skin penetration by distal nail tip, treated by trimming the nail.

found more complications and increased hospital stay duration with conservative method (26 vs 9 days) [21]. They concluded operative treatment is associated with shorter hospital stay and has financial, psychosocial and economic advantages with early return to school. The mean duration of hospital stay in our stu-

dy was 4.8 days which is comparable to other studies of Kapil Mani *et al* (4 days), Luhmann *et al* (3.4 days) and others [12, 15, 25]. The hospital stay was prolonged for patients with head trauma and one infected patient.

By preserving the fracture biology due to physiological method of fixation, union rates have been excellent with FIN. Flynn *et al*, Lohiya *et al* and Narayanan *et al* did not report any union difficulty [11, 15, 24]. Luhmann *et al* observed one case of hypertrophic nonunion and delayed union each [25]. Our average union time of nine weeks is comparable to those in above series. Transverse and short oblique closed fractures united faster than comminuted and open fractures. In our series, we had no case of nonunion and one case of delayed union (in a patient with deep infection).

Several authors have described malunion with this form of fixation. Heinrich *et al* in a study of 77 cases reported 11% coronal malalignment and 8% sagittal malalignment [26]. In Flynn's series of 58 cases, there were six cases with malalignment of 5-10° [11]. Nancy Hospital group had 14 cases of 5-10° angulation out of 123 fractures [9]. Ligier *et al* did not use any postoperative immobilisation, while Flynn *et al*, Luhmann *et al*, Moroz *et al* used selective spica cast or femoral braces in their



**Figure 6.** A. Postoperative AP and lateral radiographs of femur at 6 weeks showing varus alignment with early callus formation. B. AP and lateral radiographs at 8 months with fracture united in varus. C. After removal of nails.

series [9, 11, 25, 27]. In our series there were two cases of varus angulation of  $10^\circ$  and one case of external rotational malalignment of  $10^\circ$  (all fractures were unstable) which is less as compared to other series as we routinely used femoral bracing and delayed weight bearing in comminuted, unstable fractures. FIN is an ideal implant for transverse and short oblique fractures of midshaft femur, if used in patients with comminution or long spiral fracture configuration additional protection should be given with femoral brace, delayed mobilization or non weight bearing mobilisation. The use of FIN should be avoided in patients weighing more than 45 kgs and above 14 years of age as it does not stabilize the fracture enough and often fails on weight bearing leading to implant failure or malunion.

The presence of different nail sizes is an advantage in choosing the correct implant diameter. We used two stainless steel flexible nails of same size in all cases after determining the nail size by Flynn's formula [11]. In a series by Narayanan *et al*, mismatched and smaller nail sizes accounted for angulations and malrotations in three patients [24]. Salonen *et al* calculated nail diameter (ND)/medullary canal diameter (MD) ratio in his patients, with four patients having ND/MD ratio of  $<60\%$  and two patients requiring reoperation [23]. We did not have any problems with medullary canal and nail mismatch in our patients due to precise preoperative evaluation. While many se-

ries report lengthening after femoral fractures due to increased physal blood supply, we had no case of lengthening [28]. Kapil Mani *et al* reported four cases of lengthening (average 7 mm) while Luhmann *et al* had lengthening in six patients (average 8 mm) and shortening in two patients (average 12.5 mm) [12, 25]. We had shortening of  $<1$  cm in three patients with comminuted fractures and 18 mm shortening in a patient with deep infection. Long term follow-up is needed to determine the final leg length discrepancy at skeletal maturity.

Most authors recommend routine nail removal after union, the timing for such removal is not well defined in the literature. Despite complications after early removal, many authors have reported good outcomes after removing nails at three months [9, 11]. Most authors have typically removed nails around one year after surgery with excellent outcomes [29]. We removed nails within the first year in 18 cases and 38 cases in total till final follow-up.

Flynn *et al* had one poor result in 58 cases, while Vransky *et al* in a series of 141 fractures had universally good results without a single complication [30]. Luhmann *et al* reported a complication rate of 49%, but only two major postoperative complications [25]. Lohiya *et al* reported a complication rate of 44% with only four poor results in 73 cases [15]. We had a complication rate of 33.3% with only one major complication that included deep infection. The



## FIN in pediatric femur fractures

patient required revision surgery and had a poor outcome. Functional evaluation done by Flynn's criteria revealed excellent results in 36 patients, satisfactory in 8 and poor in 1 patient.

Our study had various limitations as we had no control group and did not compare our results with that of other methods of treatment. Although we used cheaper stainless steel nails, cost effective analysis of this treatment modality was not established in relation with conservative management or titanium elastic nails. We consider this procedure to be worthwhile in countries with limited resources and prevalent poverty. Our follow-up was medium and long term follow-up is needed to determine the effects of this procedure on final limb length discrepancy.

### Conclusion

Flexible intramedullary nailing with Stainless steel nails is an excellent choice for treatment of pediatric femur fractures. The procedure has a short learning curve with superior reproducible results and an acceptable rate of complications. It is safe, technically simple, minimally invasive, stable fixation method allowing rapid healing with early motion of adjacent joints, mobilization and return to school. The complication rate can be decreased by proper selection of patients and strict adherence to basic techniques. The indications can be expanded to include certain metaphyseal fractures. With literature advancing in favour of this procedure, FIN may become an ideal implant in managing pediatric femoral fractures in near future.

### Acknowledgements

Proper informed consent was taken from all the parents/guardians of the patients for participating in the study after explaining the procedure in detail.

### Disclosure of conflict of interest

None.

**Address correspondence to:** Dr. Tabish Tahir Kirmani, Department of Orthopedics, Teerthanker Mahaveer Medical College and Research Center, House No. 115, Lane No. 04, Omer Colony B, Lalbazar, Srinagar 190023, Jammu and Kashmir,

India. Tel: +917006559745; E-mail: tabishtahir@rediffmail.com

### References

- [1] Loder RT, O'Donnell PW and Feinberg JR. Epidemiology and mechanisms of femur fractures in children. *J Pediatr Orthop* 2006; 26: 561-566.
- [2] Henderson J, Goldacre MJ, Fairweather JM and Marcovitch H. Conditions accounting for substantial time spent in hospital in children aged 1-14 years. *Arch Dis Child* 1992; 67: 83-86.
- [3] Hedlund R and Lindgren U. The incidence of femoral shaft fractures in children and adolescents. *J Pediatr Orthop* 1986; 6: 47-50.
- [4] Younis MH, Mahmoud K, Kawas A and Ibrahim T. Early versus late hip spica casting for paediatric femoral shaft fractures. *J Pediatr Orthop B* 2019; 28: 122-126.
- [5] Kim EJ, Crosby SN Jr, Mencio GA, Green NE, Lovejoy SA, Shoenecker JG and Martus JE. Rigid intramedullary nailing of femoral shaft fractures in skeletally immature patients using a lateral trochanteric entry portal. *JBJS Essent Surg Tech* 2014; 4: e19.
- [6] Clinkscales CM and Peterson HA. Isolated closed diaphyseal fractures of the femur in children: comparison of effectiveness and cost of several treatment methods. *Orthopedics* 1997; 20: 1131-1136.
- [7] Kong H and Sabharwal S. External fixation for closed pediatric femoral shaft fractures: where are we now? *Clin Orthop Relat Res* 2014; 472: 3814-3822.
- [8] Vitiello R, Lillo M, Donati F, Masci G, Noia G, De Santis V and Maccauro G. Locking plate fixation in pediatric femur fracture: evaluation of the outcomes in our experience. *Acta Biomed* 2019; 90: 110-115.
- [9] Ligier JN, Metaizeau JP, Prevot J and Lascombes P. Elastic stable intramedullary nailing of femoral shaft fractures in children. *J Bone Joint Surg Br* 1988; 70: 74-77.
- [10] Mohamed A and Rajeev AS. Clinical outcomes and complications of titanium versus stainless steel elastic nail in management of paediatric femoral fractures-a systematic review. *Eur J Orthop Surg Traumatol* 2017; 27: 157-167.
- [11] Flynn JM, Hresko T, Reynolds RA, Blasier RD, Davidson R and Kasser J. Titanium elastic nails for pediatric femur fractures: a multi-center study of early results with analysis of complications. *J Pediatr Orthop* 2001; 21: 4-8.
- [12] Mani KCK, Raj RCD and Parimal A. Pediatric femoral shaft fractures treated by flexible intramedullary nailing. *Chin J Traumatol* 2015; 18: 284-287.

## FIN in pediatric femur fractures

- [13] Wani MM, Dar RA, Latoo IA, Malik T, Sultan A and Halwai MA. External fixation of pediatric femoral shaft fractures: a consecutive study based on 45 fractures. *J Pediatr Orthop B* 2013; 22: 563-570.
- [14] Gonzalez-Herranz P, Burgos-Flores J, Rapariz JM, Lopez-Mondejar JA, Ocete JG and Amaya S. Intramedullary nailing of the femur in children. Effects on its proximal end. *J Bone Joint Surg Br* 1995; 77: 262-266.
- [15] Lohiya R, Bachhal V, Khan U, Kumar D, Vijayvargiya V, Sankhala SS, Barghava R and Jindal N. Flexible intramedullary nailing in paediatric femoral fractures. A report of 73 cases. *J Orthop Surg Res* 2011; 6: 64.
- [16] Allen JD, Murr K, Albitar F, Jacobs C, Moghadamian ES and Muchow R. Titanium elastic nailing has superior value to plate fixation of mid-shaft femur fractures in children 5 to 11 years. *J Pediatr Orthop* 2018; 38: 111-117.
- [17] Gyaneshwar T, Nitesh R, Sagar T, Pranav K and Rustagi N. Treatment of pediatric femoral shaft fractures by stainless steel and titanium elastic nail system: a randomized comparative trial. *Chin J Traumatol* 2016; 19: 213-216.
- [18] Stans AA, Morrissy RT and Renwick SE. Femoral shaft fracture treatment in patients age 6-16 years. *J Pediatr Orthop* 1999; 19: 222-228.
- [19] Canale ST. Fracture and dislocation in children. In: Canale ST, Beaty JH, editors. *Campbell's Operative Orthopaedics*. 11th edition. Philadelphia: Mosby; 2007. pp. 1651-1661.
- [20] Buechsenschuetz KE, Mehlman CT, Shaw KJ, Crawford AH and Immerman EB. Femoral shaft fractures in children: traction and casting versus elastic stable intramedullary nailing. *J Trauma* 2002; 53: 914-921.
- [21] Reeves RB, Ballard RI and Hughes JL. Internal fixation versus traction and casting of adolescent femoral shaft fractures. *J Pediatr Orthop* 1990; 10: 592-595.
- [22] Siddiqui AA, Abousamra O, Compton E, Meisel E and Illingworth KD. Titanium elastic nails are a safe and effective treatment for length unstable pediatric femur fractures. *J Pediatr Orthop* 2020; 40: 560-565.
- [23] Salonen A, Lahdes-Vasama T, Mattila VM, Valipakka J and Pajulo O. Pitfalls of femoral titanium elastic nailing. *Scand J Surg* 2015; 104: 121-126.
- [24] Narayanan UG, Hyman JE, Wainwright AM, Rang M and Alman BA. Complications of elastic stable intramedullary nail fixation of pediatric femoral fractures, and how to avoid them. *J Pediatr Orthop* 2004; 24: 363-369.
- [25] Luhmann SJ, Schootman M, Schoenecker PL, Dobbs MB and Gordon JE. Complications of titanium elastic nails for pediatric femoral shaft fractures. *J Pediatr Orthop* 2003; 23: 443-447.
- [26] Heinrich SD, Drvaric DM, Darr K and MacEwan GD. The operative stabilization of pediatric diaphyseal femur fractures with flexible intramedullary nails: a prospective analysis. *J Pediatr Orthop* 1994; 14: 501-507.
- [27] Moroz LA, Launay F, Kocher MS, Newton PO, Frick SL, Sponseller PD and Flynn JM. Titanium elastic nailing of fractures of the femur in children. Predictors of complications and poor outcome. *J Bone Joint Surg Br* 2006; 88: 1361-1366.
- [28] Shapiro F. Fractures of the femoral shaft in children: the overgrowth phenomenon. *Acta Orthop Scand* 1981; 52: 649-655.
- [29] Morshed S, Humphrey M, Corrales LA, Millett M and Hoffinger SA. Retention of flexible intramedullary nails following treatment of pediatric femur fractures. *Arch Orthop Trauma Surg* 2007; 127: 509-514.
- [30] Vrsansky P, Bourdelat D and Al Faour A. Flexible intramedullary pinning technique in the treatment of pediatric fractures. *J Pediatr Orthop* 2000; 20: 23-27.