

Original Article

Evaluation of long term outcome of selective fusion in patients with idiopathic scoliosis

Mohammad Reza Etemadifar¹, Ali Andalib¹, Masoud Mahdinezhad Yazdi², Saeed Farzinnia²

¹Associate Professor of Spine Surgery, Department of Orthopedic Surgery, School of Medicine, Isfahan University of Medical Sciences, Isfahan, Iran; ²Department of Orthopedic Surgery, School of Medicine, Isfahan University of Medical Sciences, Isfahan, Iran

Received November 16, 2020; Accepted January 26, 2021; Epub February 15, 2021; Published February 28, 2021

Abstract: Background: Instrumented fusion is the standard treatment in adolescent idiopathic scoliosis (AIS). In patients with both thoracic and lumbar curves there is a trend toward fusing the major curve and keeping the spine mobile with greater function in the future. To evaluate the results of selective fusion in patients with AIS, we aimed to do this research in eligible patients with adolescent idiopathic scoliosis referred to educational hospitals in Isfahan, Iran. Methods: This is a retrospective cross-sectional study which was performed in 2019 in educational hospitals in Isfahan. The study population consisted of 21 patients with idiopathic scoliosis who had been treated with the selective fusion method in 2010-2018. Demographic data of patients including age, sex, and previous medical history and operation results were noted from medical documents of all patients. Cobb's angle measurements and assessments related to complications, Patients' satisfaction and outcome of the surgery were assessed using Patient Outcome Questionnaires developed by Scoliosis Research Society (SRS-22) and 36-Item Short Form Survey (SF-36) questionnaires. Results: A total of 21 patients with idiopathic scoliosis were enrolled in the study. The lowest follow-up duration was 2 years and the longest duration was 10 years. We showed that the mean upper curve before interventions were 50.66 ± 7.55 and the mean lower curve before interventions was 35.19 ± 3.86 . These amounts improved significantly after surgeries ($P < 0.001$). Evaluation of thoracic apical vertebral translation (AVT) to thoracolumbar or lumbar AVT ratio also showed significant improvements ($P < 0.001$). Conclusion: Patients undergoing selective fusion benefit from this surgical procedure. The upper and lower curves improved significantly and 85.8% of patients were satisfied with the surgery. Stopping fusion above the L2 in all patients left the lumbar spine mobile which is an important factor in patient satisfaction. We suggest that selective fusion be considered for surgical treatment of some patients with idiopathic scoliosis.

Keywords: Idiopathic scoliosis, selective fusion, prognosis, outcome

Introduction

Idiopathic scoliosis is a common cause of spine surgery among adolescents [1, 2]. About 10% of patients with a deviation of more than ten degrees require treatments. Indications for idiopathic scoliosis surgery include unacceptable progression of curvature, severe deformity (above 40 to 50 degrees depending on bone maturity), and uncontrollable pain with non-surgical methods, physical problems, thoracic lordosis [1].

Selective fusion surgery is considered in adolescents in cases where there is a curvature in the thoracic and lumbar (or thoracolumbar) spine and, fusion only is performed for one

curve. It is anticipated that another curve is corrected spontaneously. The benefit of this surgery is the limitation of fusion levels, therefore decreasing the limitation of spine motion [3, 4]. There have been some controversial results in recent data about the effectiveness of this method. Some surgeons believe that full fusion leads to greater spinal strength and excellent outcomes in treatment, while others believe that in selective fusion, with more mobility in the spine, patients could benefit from a higher level of activity and quality of life after surgery [5-7].

A study performed by the Lenke group showed that selective thoracic fusion was performed in 62% of patients with Lenke 1C curves [8]. They

Long term outcome of selective fusion

found that both the thoracic and lumbar curves are fused in 38% of the Lenke 1C curves. This is contradictory to the recommendations provided by the Lenke classification and thus the Lenke lumbar C modifier was termed a “rule breaker”. Selective fusion is a concept that has developed over this controversy and is defined in this review as isolated thoracic fusion with Lenke 1C, 2C, some 3C, and some 4C curves as well as isolated thoracolumbar/lumbar curves in Lenke 5C and some 6C curves. The most important factor in performing or not performing this surgery is the patient’s lifestyle (activity level, age, being an athlete). The outcomes of this surgery depend on various factors and we believe that most patients could benefit from selective fusion surgery [9]. The difficulty now lies in determining which patients should undergo selective fusion and which vertebrae should be included in the fusion. Many parameters must be considered when evaluating a patient for the selective fusion of either the main thoracic or thoracolumbar/lumbar curves including patient lifestyle and expectation as well as guidelines for selective fusion, fusion levels, amount of curve correction, and potential complications. Therefore, due to the high prevalence of idiopathic scoliosis and the need to adopt the most appropriate surgical method and on the other hand the lack of sufficient studies in Iran on the results of this treatment, this study, we aimed to evaluate the results of selective fusion in patients with idiopathic scoliosis referred to educational hospitals in Isfahan, Iran. Most of the previous studies have been conducted in variable populations and reported different results. There has not been any similar study in the Iranian population so far and this is the first study conducted on patients with idiopathic scoliosis in Iran.

Methods and material

Study design

This is a retrospective cross-sectional study which was performed in 2019 in educational hospitals in Isfahan. The study population consisted of 21 patients with idiopathic scoliosis who had been treated with the selective fusion method in 2010-2018. The current study was approved by the Research Committee of Isfahan University of Medical Sciences and the Ethics committee has confirmed it.

Inclusion and exclusion criteria

The inclusion criteria were: diagnosis of idiopathic scoliosis by an expert spine surgeon and his fellowship, treatments with selective fusion method between September 2010 until November 2018 in educational hospitals in Isfahan, accessibility to medical records of patients, accessibility to patients for further visits and follow-ups and signing the written informed consent to participate in this study. The exclusion criteria were: having spinal surgery more than once and over 20% defect in the medical records.

Measuring tools

Twenty-one patients were enrolled in the study based on the census method. Demographic data of patients including age, sex, and previous medical history and operation results were noted from medical documents of all patients. Initial Cobb’s angles were also noted from medical records. The patients were called and visited during the study and underwent radiological examination for Cobb’s angle measurements and assessments related to complications such as coronal decompensation. Patients’ satisfaction with the outcome of the surgery was assessed in the form of a Likert option as completely satisfied, satisfied, no opinion, dissatisfied and completely dissatisfied. The outcome of surgery was assessed using Patient Outcome Questionnaires developed by the Scoliosis Research Society (SRS) [10]. This questionnaire has 22 items that evaluate the patient’s feelings and physical activities. A 36-Item Short Form Survey (SF-36) was also filled for each patient. This questionnaire is an oft-used, well-researched, self-reported measure of health covering eight domains of health [11].

Statistical analysis

After collecting the study data, they were entered into SPSS software (version 25, IBM Corporation, Armonk, NY) and analyzed. Qualitative variables were compared using χ^2 and quantitative variables were compared using Paired T-test. Wilcoxon nonparametric test was also used. Quantitative variables had a normal distribution and a standard deviation was presented. In all tests, values of $P < 0.05$ were considered as a significant level.

Long term outcome of selective fusion

Table 1. Demographic data of patients

Variable	Number (%)
Gender	Male 5 (23.8%)
	Female 16 (76.2%)
Age (mean \pm SD)	15.52 \pm 5.48
Follow up time (mean \pm SD)	3 \pm 1.05

SD: standard deviation.

Results

Population

A total number of 21 patients with idiopathic scoliosis entered the study. The study population consisted of 5 males (23.8%) and 16 females (76.2%). The mean age of the patients was 15.52 \pm 5.48 years. The lowest follow-up duration was 2 years and the longest duration was 10 years. The demographic data of patients are summarized in **Table 1**.

Evaluation of spinal curves

The mean upper curve before interventions was 50.66 \pm 7.55 and the mean upper curve after interventions were 11.57 \pm 8.33 that indicates 39.09 degrees improvements in the upper curve. Our data also showed that the mean lower curve before interventions was 35.19 \pm 3.86 and after selective fusion surgeries, the mean for lower curve improved 27.61 degrees and became 7.57 \pm 5.1. Evaluation of thoracic apical vertebral translation (AVT) to thoracolumbar or lumbar AVT ratio also showed significant improvements. The mean AVT ratio before surgeries was 1.45 \pm 0.15 and after interventions were 1.13 \pm 0.2. These amounts changed significantly based on our data analysis ($P < 0.001$) (**Table 2**; **Figure 1**). These data showed improvements in both upper and lower curves in patients.

Further variables

We should also note that none of the patients had progression of deformity, adding on deformity, coronal decompensation and repeated surgery. Analysis of patient satisfaction also showed that 85.8% of patients were satisfied and totally satisfied with the surgical results and only 9.2% were not satisfied.

Analysis of pain in patients showed that 38.1% of patients had no pain within the past 6

months and only 4.8% had severe pain. Assessments of the physical activities of patients showed that 52.4% could perform slight daily activities and 9.5% of patients could not perform any activity. Totally, 71.5% of patients reported 75-100% of activities. Furthermore, 90.5% of patients reported no limitations in walking almost 100 meters in the outside environment and also reported no limitations in activities such as dressing or bathing.

Pain and analgesic consumption

We also showed that 52.3% of patients had no or seldom low back pain during resting within the past 6 months. Based on our data, 90.5% of patients used no analgesics and 9.5% of them consumed weekly non-opioids as analgesics. We also showed that 33.3% of patients have experienced sadness of feeling of depression in the past 6 months.

Post-operative complications

Assessments of post-operative complications showed that none of the patients had coronal imbalance, add on the deformity and progression of the deformity. Only one case had wound discharges two years after the surgery and one other patient had a fracture in the last screw (in the L1 vertebrae). We should also note that these two patients had no significant restriction in daily activities, no acute, or severe pain or no other issues.

Discussion

In the present study, we investigated and evaluated 21 patients with idiopathic scoliosis who had been treated with selective fusion surgery and indicated significant improvements in both upper and lower curves in patients. We also declared that the thoracic AVT to thoracolumbar or lumbar AVT ratio improved significantly compared to before surgeries. Our results also showed none of the patients had progression of deformity, adding on deformity, coronal decompensation and repeated surgery. Evaluation of patient satisfaction showed that 85.8% of patients were satisfied and totally satisfied with the surgical results. Our data also showed that 52.3% of patients had no or seldom low back pain during resting within the past 6 months. Based on our data, 90.5% of patients used no analgesics and 9.5% of them consumed weekly non-opioids as analgesics.

Long term outcome of selective fusion

Table 2. Comparison of upper and lower curves and AVT ratio in patients

Variable	Mean	SD	Improvements	P-value
Upper curve before (degree)	50.66	7.55	39.09°	<0.001
Upper curve after (degree)	11.57	8.33		
Lower curve before (degree)	35.19	3.86	27.61°	<0.001
Lower curve after (degree)	7.57	5.1		
AVT ratio before	1.45	0.15	0.32	<0.001
AVT ratio after	1.13	0.2		

SD: standard deviation, AVT: apical vertebral translation. Due to the non-normality of the data, Wilcoxon nonparametric test was used. Values of $P < 0.05$ indicate a significant difference in the mean of variables before and after surgery. °: degree.

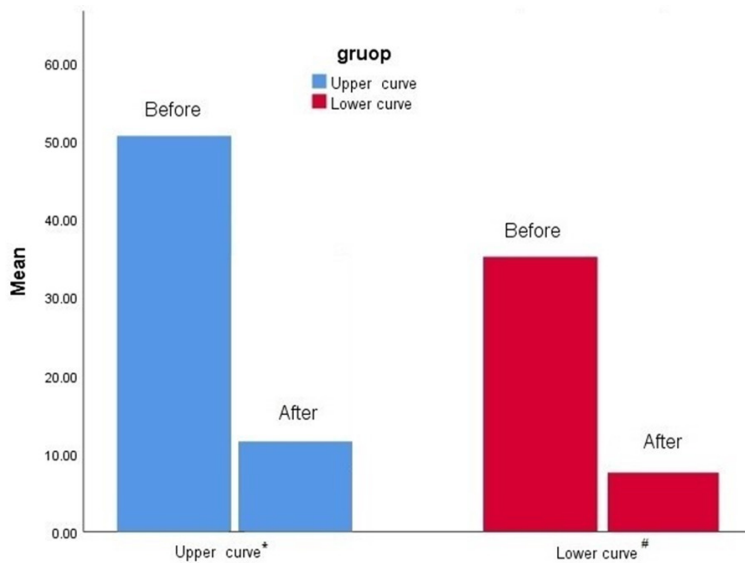


Figure 1. Changes in upper and lower curves in patients. *Significant reduction in upper curves were observed after surgeries (50.66 ± 7.55 vs. 11.57 ± 8.33 , $P < 0.001$). #Significant reduction in lower curves were observed after surgeries (35.19 ± 3.86 vs. 7.57 ± 5.1 , $P < 0.001$).

The findings of the present study emphasized the effectiveness of selective fusion surgery in patients with idiopathic scoliosis. There have been also some previous studies in this regard. Most of the previous studies have investigated the proper indications for selective fusion and very few have evaluated the long term prognosis of patients. A study was performed by Suk and colleagues in 2005 that evaluated the long-term prognosis of 203 patients with idiopathic scoliosis treated with selective fusion. They declared that selective fusion is associated with satisfactory radiographic and clinical outcomes after surgery and has been well-maintained for a minimum 5-year follow-up [12]. Studer and others also investigated 157 patients within an 11-years study period in 2015 and showed that selective fusion surgery

results in significantly improved spinal curves and also improvements in AVT ratio. In this study, it was also stated that selective fusion might be associated with complications including adding on the deformity and coronal decompensation [5]. These results were also confirmed by Crawford and colleagues in their study in 2013. They showed that both upper and lower spinal curves could significantly improve following selective fusion in most patients [13]. Our results were also in line with our findings that indicate beneficial effects of selective fusion surgery on spinal curves and AVT ratio. But as mentioned earlier, none of our patients had progression of deformity, adding on deformity, coronal decompensation and repeated surgery.

Another study was performed by Larson and others in 2012 on 19 patients with idiopathic scoliosis. It was stated that spinal balance and correction of the lumbar curve remain stable over time in selective fusion surgery [14]. The same results were reported by Delfino and others in 2017. They evaluated 42 patients that have been treated with selective fusion.

Furthermore, they showed that selective anterior thoracolumbar instrumentation with a single solid rod in adolescent idiopathic scoliosis (AIS) maintained good corrections on the three planes with no major complications or infections, no revision surgeries, and with satisfactory final functional and clinical outcomes in long term follow up [15]. It was also showed that 80% of patients satisfied with their surgical results. These results are in line with the findings of our study. A key point of the current study is that we evaluated the patient's satisfaction and low back pain and consumption of analgesics within 2 years follow-up.

Senkoylu and others also showed that selective fusion resulted in improvements in both thoracic and lumbar Cobb angle in patients and

also significantly reduced the AVT ratio [16]. As mentioned, previous studies have mostly focused on the changes in spinal curves and radiographic and clinical outcomes [17-19]. Our results were in line with the former studies emphasizing the reduction in both upper and lower curves along with the reduction in AVT ratio. An important aspect of our study was that we evaluated the clinical and radiological results of selective fusion along with assessments of patient's pain, physical activities, satisfaction and other factors.

Matsumoto and colleagues explained that selective fusion could influence the health-related quality of life in patients by improving their ability to perform their daily activities [20]. Enercan and colleagues also compared the quality of life and satisfaction in adolescents with idiopathic scoliosis and showed that apart from improvements in spinal curves, the quality of life of these patients could be similar to the normal population in years after surgeries [21]. Our results are in line with these findings.

Another aspect of this surgery is the preservation of more motion segments. During elective fusion, L2, L3, L4 and L5 vertebrae are not included in fusion thereby range of motion is preserved. It was also reported that patients undergoing longer fusions had serious problems in sitting and bending their spine. We believe that the absence of such problems could be accounted for important advantages of selective fusion surgery. Here we had a retrospective evaluation of patient's documents. The limitations of this study were that this study could have unknown potential confounders, we used the data that were originally collected for these purposes, not all the relevant information, and we had also inferior level of evidence compared with prospective studies. We also had restricted study population compared to some former studies and therefore, suggest that more studies on larger populations should be performed.

Conclusion

Here we showed that the patients undergoing selective fusion benefit from this surgical procedure. The upper and lower curves and also AVT ratio of patients improved significantly and 85.8% of patients were satisfied. These data were in line with the findings of most previous studies. As a result, we suggest that orthopedic

surgeons should pay more attention to this surgical technique in patients with idiopathic scoliosis.

Disclosure of conflict of interest

None.

Address correspondence to: Masoud Mahdinezhad Yazdi, Department of Orthopedic Surgery, School of Medicine, Isfahan University of Medical Sciences, Hezar Jarib St., Isfahan, Iran. Tel: +989124471225; E-mail: 19mmy72@gmail.com

References

- [1] Negrini S, Donzelli S, Aulisa AG, Czaprowski D, Schreiber S, de Mauroy JC, Diers H, Grivas TB, Knott P and Kotwicki T. 2016 SOSORT guidelines: orthopaedic and rehabilitation treatment of idiopathic scoliosis during growth. *Scoliosis Spinal Disord* 2018; 13: 3.
- [2] Choudhry MN, Ahmad Z and Verma R. Adolescent idiopathic scoliosis. *Open Orthop J* 2016; 10: 143.
- [3] Clément JL, Pelletier Y, Solla F and Rampal V. Surgical increase in thoracic kyphosis increases unfused lumbar lordosis in selective fusion for thoracic adolescent idiopathic scoliosis. *Eur Spine J* 2019; 28: 581-589.
- [4] Lin Y, Chen W, Chen A, Li F and Xiong W. Anterior versus posterior selective fusion in treating adolescent idiopathic scoliosis: a systematic review and meta-analysis of radiologic parameters. *World Neurosurg* 2018; 111: e830-e844.
- [5] Studer D, Awais A, Williams N, Antoniou G, Eardley-Harris N and Cundy P. Selective fusion in adolescent idiopathic scoliosis: a radiographic evaluation of risk factors for imbalance. *J Child Orthop* 2015; 9: 153-160.
- [6] Bosch P, Kenkre TS, Londino JA, Cassara A, Yang C and Waters JH. Coagulation profile of patients with adolescent idiopathic scoliosis undergoing posterior spinal fusion. *JBJS* 2016; 98: e88.
- [7] Jiang J, Qian BP, Qiu Y, Wang B, Yu Y and Zhu ZZ. Full fusion of proximal thoracic curve helps to prevent postoperative cervical tilt in Lenke type 2 adolescent idiopathic scoliosis patients with right-elevated shoulder. *BMC Musculoskelet Disord* 2017; 18: 1-7.
- [8] Lenke LG, Betz RR, Clements D, Merola A, Haher T, Lowe T, Newton P, Bridwell KH and Blanke K. Curve prevalence of a new classification of operative adolescent idiopathic scoliosis: does classification correlate with treatment? *Spine* 2002; 27: 604-611.
- [9] Scaramuzzo L, Giudici F, Bongetta D, Caboni E, Minoia L and Zagra A. Thoraco-lumbar selec-

Long term outcome of selective fusion

- tive fusion in adolescent idiopathic scoliosis with Lenke C modifier curves: clinical and radiographic analysis at 10-year follow-up. *Eur Spine J* 2017; 26: 514-523.
- [10] Monticone M, Nava C, Leggero V, Rocca B, Salvaderi S, Ferrante S and Ambrosini E. Measurement properties of translated versions of the Scoliosis Research Society-22 Patient Questionnaire, SRS-22: a systematic review. *Qual Life Res* 2015; 24: 1981-1998.
- [11] Laddu DR, Wertheim BC, Garcia DO, Woods NF, LaMonte MJ, Chen B, Anton-Culver H, Zaslavsky O, Cauley JA and Chlebowski R. 36-item short form survey (SF-36) versus gait speed as predictor of preclinical mobility disability in older women: the women's health initiative. *J Am Geriatr Soc* 2018; 66: 706-713.
- [12] Suk SI, Lee SM, Chung ER, Kim JH and Kim SS. Selective thoracic fusion with segmental pedicle screw fixation in the treatment of thoracic idiopathic scoliosis: more than 5-year follow-up. *Spine* 2005; 30: 1602-1609.
- [13] Crawford CH 3rd, Lenke LG, Sucato DJ, Richards BS 3rd, Emans JB, Vitale MG, Erickson MA and Sanders JO. Selective thoracic fusion in Lenke 1C curves: prevalence and criteria. *Spine* 2013; 38: 1380-1385.
- [14] Larson AN, Fletcher ND, Daniel C and Richards BS. Lumbar curve is stable after selective thoracic fusion for adolescent idiopathic scoliosis: a 20-year follow-up. *Spine* 2012; 37: 833-839.
- [15] Delfino R, Pizones J, Ruiz-Juretschke C, Sánchez-Mariscal F, Zúñiga L and Izquierdo E. Selective anterior thoracolumbar fusion in adolescent idiopathic scoliosis: long-term results after 17-year follow-up. *Spine* 2017; 42: E788-E794.
- [16] Senkoylu A, Luk KD, Wong YW and Cheung KM. Prognosis of spontaneous thoracic curve correction after the selective anterior fusion of thoracolumbar/lumbar (Lenke 5C) curves in idiopathic scoliosis. *Spine J* 2014; 14: 1117-1124.
- [17] Frez R, Cheng JC and Wong EM. Longitudinal changes in trunkal balance after selective fusion of King II curves in adolescent idiopathic scoliosis. *Spine* 2000; 25: 1352-1359.
- [18] Solla F, Gallo M, Doria C, Caci H, Voury A, Rosello O, Clément JL and Rampal V. Prognostic role of rib hump in overlying thoracic curve correction above selective fusion for Lenke 5 idiopathic adolescent scoliosis. *Clin Spine Surg* 2018; 31: E140-E145.
- [19] Ting W, Xu JG and Zeng BF. Selective fusion in adolescent idiopathic scoliosis. *Chin Med J* 2008; 121: 1456-1461.
- [20] Matsumoto H, Colacchio ND, Schwab FJ, Lafage V, Roye DP and Vitale MG. Flatback revisited: reciprocal loss of lumbar lordosis following selective thoracic fusion in the setting of adolescent idiopathic scoliosis. *Spine Deform* 2015; 3: 345-351.
- [21] Enercan M, Kahraman S, Cobanoglu M, Yilar S, Gokcen BH, Karadereler S, Mutlu A, Ulusoy LO, Ozturk C and Erturer E. Selective thoracic fusion provides similar health-related quality of life but can cause more lumbar disc and facet joint degeneration: a comparison of adolescent idiopathic scoliosis patients with normal population 10 years after surgery. *Spine Deform* 2015; 3: 469-475.