

## Case Report

# Burns and patients infected with COVID-19 at a burn treatment centre in Brazil: a series of case-reports

Thiago Maciel Valente<sup>1</sup>, Fernanda Assunção Tiraboschi<sup>1</sup>, Ítalo Souza Oliveira Santos<sup>2</sup>, Maria Eliane Maciel de Brito<sup>2</sup>, Thais Maciel Valente<sup>1</sup>, Guilherme Pinheiro Ferreira da Silva<sup>1,2</sup>

<sup>1</sup>University of Fortaleza, Fortaleza, Ceará, Brazil; <sup>2</sup>Burn Care Department from Doctor José Frota Institute, Fortaleza, Ceará, Brazil

Received June 5, 2021; Accepted September 26, 2021; Epub October 15, 2021; Published October 30, 2021

**Abstract:** Background: In December 2019, in Wuhan, China, several cases of viral pneumonia, caused by a new type of coronavirus (SARS-CoV-2, a disease that became known as COVID-19) emerged. Being an alarming situation, many resources were directed to fight this pandemic. However, other diseases and conditions, such as burn injuries, continued to occur in this period, thus creating multiple challenges. Method: Four patients with COVID-19 treated in a reference burn treatment centre from the Northeast region of Brazil, in the city of Fortaleza were analysed between April to June 2020. Results: All patients were admitted in the service without signs of COVID-19 infection; however the symptoms appeared a few days after hospitalisation. The most common symptom was fever, especially when it occurred in only one spike. Patients who evolved to an unfavourable outcome had comorbidities prior to the infection and burn injury. In addition to this, these two patients had a worsening of their renal function, in contrast to the other two patients that received hospital discharge. Conclusion: The burned patient is a complex one that requires the health professional's attention and special care. This became even more evident during the period of the COVID-19 pandemic. Thus, the patients' changes and symptoms must be cautiously analysed, their diagnosis should not be delayed and it must be made under standardised protocols accordingly with the socio-economic and cultural realities of each service.

**Keywords:** "Burns", "burn units", "COVID-19"

## Introduction

In December 2019, several cases of viral pneumonia, caused by a new type of coronavirus (SARS-CoV-2, a disease that became known as COVID-19) quickly spread itself being considered by the World Health Organization (WHO), on the 30<sup>th</sup> of January 2020, as a global health emergency [1, 2].

For being an alarming situation, many resources were directed to fight this pandemic. Furthermore, it is still a new disease whose effects on the health system of each country are unknown, thus creating uncertainties about the real consequences in each place [3]. However, other diseases and conditions, such as burn injuries, continued to happen in this period, resulting in several challenges for the safe care of patients with common conditions that were already occurring before the pandemic.

According to the WHO, in 2014 there were more than 11 million burns requiring medical care worldwide, which, when not fatal, are important causes of morbidity and interference in quality of life [4]. Under data from DATA-SUS, a digital tool from the Brazilian Ministry of Health that allow the access to information from the country's health system, until May 2020, more than 10 thousand hospitalisations by burn injuries occurred, even being similar than the previous year in the same period (approximately 11 thousand hospitalisations in 2019) [5].

Therefore, burns continued to occur in the same proportion as previous years [6], however in 2020, they happened in a pandemic context of an intensely contagious disease, which demanded adaptations from the care services to the burned patient.

The current study's objective is to describe a few case series of patients that were victims of

burns and also were infected by COVID-19, sharing the experience of a team from the burn treatment centre of a Brazilian state, as well as to describe the hardships regarding the care to this type of patient in a developing nation, thus helping other centres to make their protocols to take care of burns patients with COVID-19, especially to countries that have economic difficulties and to alert about the similarity between the COVID-19 disease and acute injuries, as burns.

### Material and method

The current study followed the recommendations from the guidelines of The Case Report (CARE) [7] and was approved by the committee of ethics (approval number: 4.184.504) from the institution where it was accomplished concerning all ethical principles.

Four patients with COVID-19 treated in a reference burn treatment centre from the Northeast region of Brazil, in the city of Fortaleza were analysed (**Table 1**). The study occurred from April to June 2020, having the following inclusion conditions: victims of burn injuries that had laboratory results confirming the infection by COVID-19.

In our study, the disease's first day (D1) was considered as the day when the burn injury happened, the designation of days using the letter "D" and the number of the day when the event occurred after the injury.

### Case reports

#### Case 1

Male patient, 72 years old, bearer of Systemic Arterial Hypertension (SAH), obesity and glaucoma. He was hospitalized because of a second-degree burn by a flammable liquid, due to a suicide attempt, having 19% of the total body surface area (TBSA) burned. He was admitted in the burn treatment centre without fever or respiratory symptoms, showing good oxygen saturation in ambient air.

On the eighth day after admission (D8), during the balneotherapy, the patient had a sudden drop in oxygen saturation (85%), even with the use of supplementary oxygen. It was performed a chest radiography that highlighted a bilateral interstitial infiltrate.

A computerized tomography (CT) was requested, which demonstrated injuries in bilateral diffuse ground-glass opacity, affecting 75% of the lungs. The patient reported a positive result in the quick test for COVID-19 and orotracheal intubation was needed. Lymphopenia, worsening of the renal function and respiratory acidosis were shown in the laboratory exams.

The patient accomplished three balneotherapies and a bandage with silver sulfadiazine was made to cover the burn injury, being changed in alternate days before the hospitalisation at the COVID-19 ward. In addition to the attempt of using medications such as azithromycin and hydroxychloroquine, respiratory physiotherapy and oral hygiene were frequently made.

He also presented a deepening of the burns, thus surgical debridement was indicated, however due to the haemodynamic instability, the surgery was not made and the bandages were kept being changed by the team from the burn treatment centre in the COVID-19 patient's ward, due to unfavourable clinical conditions for the transference.

On D9 and D10, the patient had anuria and haemodynamic instability, thus needing vasoactive drugs. On D12, haemodialysis was accomplished. The patient remained unstable, due to this palliative care was requested on D14 and his death occurred on D15.

#### Case 2

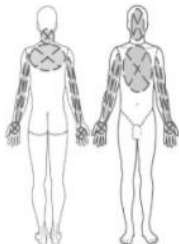
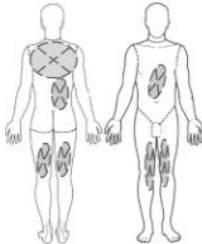
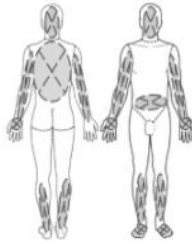
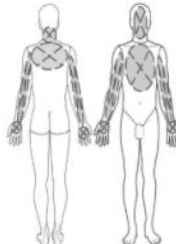
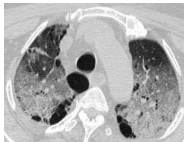

Female patient, 31 years old, at 30 weeks of gestation, without comorbidities and a tobacco user. She was admitted in the service because of second and third-degree burns by an accidental flammable liquid, having 29% of the TBSA burned.

She remained stable and asymptomatic up to two days after admission, only presenting leukopenia with lymphopenia in the complementary exams. However, on the third day after admission (D3), the patient had feverish spikes. During D4 to D8, the patient remained without fever, being only under epidemiological surveillance.

The patient was submitted to three balneotherapies and one surgical debridement during the

## Burns in COVID-19 patients

**Table 1.** Summary of cases

Patient	1	2	3	4
Risk condition	Obesity, SAH, Glaucoma	Pregnant woman, Tobacco user	Without comorbidities	Without comorbidities
Burned body surface				
Imaging scans		Did not accomplish		Did not accomplish
Blood count	Lymphopenia	Anaemia and Lymphopenia	D11: Neutrophilia, lymphopenia, anaemia and mild platelets D24: mild platelets and neutrophilia	Lymphopenia
Renal function	Altered D9: Creatinine (1.6 mg/dl) Urea (90 mg/dl) D10: Creatinine (3.5 mg/dl) Urea (144 mg/dl) D14: Creatinine (5.1 mg/dl) Urea (156 mg/dl)	Altered D9: Creatinine (1.4 mg/dl) Urea (96 mg/dl)	Normal	Normal
First symptom	Dyspnoea and sudden decrease of O2 saturation	Feverish spike	Fever	Feverish spike
Diagnostic method	Rapid test	Oropharyngeal swab	Rapid test	Rapid test
Accomplishment of Orotracheal intubation	It was performed	There was not enough time	It was not needed	It was not needed
Outcome	Death on D15	Death on D10	Hospital discharge on D72	Hospital discharge on D16

hospitalisation period. A bandage with silver sulfadiazine was made to cover the burn injury.

On D9, she presented dyspnoea, agitation, required supplementary oxygen through Venturi's mask and started antibiotics (meropenem and vancomycin). During the clinical evaluation, the foetal heartbeats were regular, however, she presented worsening of the renal function and the lymphopenia became more pronounced.

Furthermore, at D10, the patient remained without fever and with dyspnoea, however, presented anuria. The patient and the foetus died on D10, the oropharyngeal swab was collected after cardiopulmonary resuscitation (CPR) to confirm the infection by COVID-19.

### Case 3

Male patient, 33 years old, without comorbidities. He was admitted in hospital because of a second-degree burn by a flammable liquid, having 60% of the TBSA burned. The patient was admitted without respiratory symptoms. On the ninth day of admission (D9), the patient presented spikes of fever and leukopenia in the complete blood count. Nevertheless the infection by COVID-19 was not considered, because this was a large burn patient who had undergone surgical procedures and was wearing a chest drain due to a previous pneumothorax.

On D15, the patient had fever once again, however the blood count suggested bacterial infection.

## Burns in COVID-19 patients

On D24, the patient made the rapid test for COVID-19 with a positive result due to the contact with patient four from the current study, thus presenting positive IgM and IgG. Chest CT scan showed bilateral ground-glass lesions. On D30, the patient had a sharp increase in the D-dimer.

Thirteen surgical procedures were made, such as surgical debridement, balneotherapies and skin grafts. Regarding the isolation period, bandaging was made with silver foam on D32 and subsequently, with non-adhering gauze with essential fatty acids and copaiba.

Furthermore, on D48, the patient made another test for COVID-19 and since it did not show any more evidence of transmission, he remained only at the burn treatment centre. He was discharged on D72.

### Case 4

Male patient, 32 years old, without cardiovascular comorbidities, bearer of anxiety disorder. Admitted without signs of COVID-19 infection in the service because of a second-degree burn by hot oil, corresponding to 30% of the TBSA.

During hospitalisation, the patient has presented feverish spike three days after admission (D4) and has shown lymphopenia on D5. He remained afebrile and asymptomatic on the subsequent days, however on D10 he had an increase of D-dimer, having a positive result on the COVID-19 rapid test, thus was transferred to a specific ward. He remained stable, without the need for oxygen therapy.

Four balneotherapies and one surgical cleaning were made during hospitalisation in a burn treatment centre. The injury's coverage was a non-adherent net embedded with copaiba and melaleuca. He remained stable and was discharged from the hospital on D16.

### Discussion

In the current study, all patients were admitted in the service without signs of COVID-19 infection and only presented the symptoms a few days after hospitalisation. It was observed that the first most common symptom was fever, especially when it only occurred in one spike.

The patients that evolved to an unfavourable outcome, had comorbidities that preceded the

infection and the burn injury. In addition to this, these two patients had a worsening of their renal functions, in contrast to the other two patients that received hospital discharge.

A relevant factor that interfered in the patients' early diagnosis were the socioeconomic difficulties related to the public health system, since the availability of the COVID-19 exams were scarce, especially in the pandemic's beginning. Therefore, the health professionals had hardships in understanding if some symptoms of these patients were related to COVID-19 or to the burned patient's own physiological changes.

Thereby, some patients had their diagnosis delayed because clinical presentation was not so suggestive to the disease, with subtle and nonspecific symptoms associated with the lack of respiratory symptoms. Due to this, laboratory exams were needed for the diagnosis of COVID-19.

Another factor that created difficulties in these patients' handling, at the pandemic's beginning, was the lack of standardised protocols during service, which made a few patients have their diagnosis delayed, thus allowing the possible infection of other patients and professionals.

The Brazilian public health system has some socioeconomic and cultural particularities that influence the protocols to be adopted, which differ from other countries. Such as Shanghai, in China, and Barcelona, in Spain, which perform, respectively, even in asymptomatic patients admitted, chest CT and Chest X-ray [8].

In Birmingham, UK, patients with less than 10% TBSA burns are generally not admitted during the pandemic, instead health education is provided for the patient or family member to change the bandage, with virtual monitoring through telemedicine [8], which is not feasible in the Brazilian context. Another alternative to decrease the attendance in tertiary services, which were already overloaded with severe cases of COVID-19, was carried out in Malaysia by redirecting minor burn cases to primary care [9].

Currently, based on the experiences with patients infected by COVID-19, the burn treatment centre has adopted a standardized pro-

tolocol for the care of burn victims who require hospital admission. Thus, all patients admitted, even if asymptomatic and without epidemiological history of COVID-19, are required to undergo RT-PCR before any procedure and hospital admission.

In the service where the study was carried out, the bandage with silver sulfadiazine is usually changed in alternate days; however, the frequent change could pose a risk to the patient and to the healthcare team, since all the bandages are performed by the staff of the burn treatment centre, regardless of the ward in which the patient is hospitalized.

Therefore, some protocols advise to reduce the frequency of bandage changes according to the degree of exudation and healing of the wound, being an alternative option the use of foam or negative pressure bandages, which can remain longer, without needing to be changed [10].

The attempt to use silver foam was adopted in cases 3 and 4, and proved to be an important strategy to reduce the need for bandage change and the number of professionals in contact with the infected patient, since changing the bandage would require the displacement of staff from the burn treatment centre to the ward of patients infected with COVID-19, which could cause contamination of professionals and consequently of patients in the ward for non-infected burn patients.

The burn patient presents several physiological changes due to his thermal injury, especially when it is a big one. Some of the systems that suffer alterations are the immune and hematologic systems, thus causing symptoms and laboratory findings that could coincide with other clinical conditions [11].

The complexity of the burn patient was highlighted in our study. The fever spike may occur due to the inflammatory response of these patients and disguise an infectious disease, since it is possible to attribute the fever to the burn injury, especially when it occurs in the absence of other symptoms. This is possibly what occurred in cases 2, 3, and 4.

Another misleading factor is laboratory tests, since lymphopenia can be attributed to an infectious disease, such as COVID-19 [12]. There are also other conditions, such as severe

infections and even the use of silver sulfadiazine in bandaging, that can cause leukopenia with lymphopenia [13-15].

General physiological changes occurring immediately after burn injury are important for the initial survival of the patient. Microthrombi formation within the immediate vicinity of burn injury is essential for maintaining the integrity of the microvasculature surrounding the burn wound [16]. The alterations in the coagulation system occur due to the inflammation and vascular injury itself, healthcare professionals must be prepared to intervene with vigorous hydration, as well as to deal with complications such as sepsis and increased consumption of clotting factors, tending to present a procoagulant potential in the first 48 hours, which may remain for days to weeks [17, 18].

The infection by COVID-19 was also shown as a possibility to cause disorders in the coagulation, thus increasing the exams related to coagulation, especially the D-dimer, which was an important factor for the mortality's increase when higher than 1 µg/mL [19, 20].

In our study, the D-dimer has increased in cases 3 and 4, both patients were discharged from the hospital. Therefore, exams that evaluate coagulation are also possible misleading factors, among the physiological alterations in burn patients, COVID-19 infection, or both concomitant.

### Conclusion

In conclusion, two patients died, meanwhile, the other two, who did not have comorbidities or risk factors, received hospital discharge, although they remained hospitalized for a long period. The burn patient is a complex one that requires the health professional's attention and special care. This became even more evident during the period of the COVID-19 pandemic. Thus, the patients' changes and symptoms must be cautiously analysed, their diagnosis should not be delayed and it must be made under standardised protocols accordingly with the socio-economic and cultural realities of each service.

### Disclosure of conflict of interest

None.



## Burns in COVID-19 patients

**Address correspondence to:** Thiago Maciel Valente, Av. Washington Soares, 1321 - Edson Queiroz, Fortaleza, Ceará 60811-905, Brazil. E-mail: maciel.thiago@edu.unifor.br

### References

- [1] Huang C, Wang Y, Li X, Ren L, Zhao J and Hu Y. Clinical features of patients infected with 2019 novel coronavirus in Wuhan, China. *Lancet* 2020; 395: 497-506.
- [2] Velavan TP and Meyer CG. The COVID-19 epidemic. *Trop Med Int Health* 2020; 25: 278-280.
- [3] de Souza Ferreira LP, Valente TM, Tiraboschi FA and da Silva GPF. Description of COVID-19 cases in Brazil and Italy. *SN Compr Clin Med* 2020; 2: 497-500.
- [4] World Health Organization. Burns, <https://www.who.int/news-room/fact-sheets/detail/burns>; 2018 [accessed 11 August 2020].
- [5] Ministério da Saúde do Brasil - Sistema de Informações Hospitalares do SUS. DATA-SUS: queimaduras e corrosões, <http://tabnet.datasus.gov.br/cgi/tabcgi.exe?sih/cnv/niuf.def>; [accessed 11 August 2020].
- [6] Valente TM, Ferreira LPS, Silva RAD, Leite JMRS, Tiraboschi FA and Barboza MCC. Brazil COVID-19: change of hospitalizations and deaths due to burn injury? *Burns* 2020; 47: 499-501.
- [7] Riley DS, Barber MS, Kienle GS, Aronson JK, von Schoen-Angerer T, Tugwell P, Kiene H, Helfand M, Altman DG, Sox H, Werthmann PG, Moher D, Rison RA, Shamseer L, Koch CA, Sun GH, Hanaway P, Sudak NL, Kaszkin-Bettag M, Carpenter JE and Gagnier JJ. CARE guidelines for case reports: explanation and elaboration document. *J Clin Epidemiol* 2017; 89: 218-235.
- [8] Barret JP, Chong SJ, Depetris N, Fisher MD, Luo G and Moiemmen N. Burn center function during the COVID-19 pandemic: an international multi-center report of strategy and experience. *Burns* 2020; 46: 1021-1035.
- [9] Ilenghoven D, Hisham A, Ibrahim S and Yussof SJ. Restructuring burns management during the COVID-19 pandemic: a Malaysian experience. *Burns* 2020; 46: 1236-1239.
- [10] Saha S, Kumar A, Dash S and Singhal M. Managing burns during COVID-19 outbreak. *J Burn Care Res* 2020; 41: 1033-1036.
- [11] Osuka A, Ogura H, Ueyama M, Shimazu T and Lederer JA. Immune response to traumatic injury: harmony and discordance of immune system homeostasis. *Acute Med Surg* 2014; 1: 63-69.
- [12] Guan W, Ni Z, Hu Y, Liang W, Ou C and He J. Clinical characteristics of coronavirus disease 2019 in China. *N Engl J Med* 2020; 382: 1708-1720.
- [13] Manning J. Critical care nursing clinics of North America. *Sepsis in the Burn Patient* 2018; 30: 423-430.
- [14] Fuller FW. The side effects of silver sulfadiazine. *J Burn Care Res* 2009; 30: 464-470.
- [15] Fraser GL and Beaulieu JT. Leukopenia secondary to sulfadiazine silver. *JAMA* 1979; 241: 1928-9.
- [16] Lavrentieva A, Kontakiotis T, Bitzani M, Papaioannou-Gaki G, Parlapani A and Thomareis O. Early coagulation disorders after severe burn injury: impact on mortality. *Intensive Care Med* 2008; 34: 700-706.
- [17] Esp RC, Coyotzin AT, Escamilla MAG, Pérez HS, Córdova DMC and Córdova CAC. Alteraciones de la hemostasia en el enfermo con quemaduras. *Medicina Crítica* 2018; 32: 41-47.
- [18] Ball RL, Keyloun JW, Brummel-Ziedins K, Orfeo T, Palmieri TL, Johnson LS, Moffatt LT, Pusateri AE and Shupp JW. Burn-induced coagulopathies: a comprehensive review. *Shock* 2020; 54: 154-167.
- [19] Levi M, Thachil J, Iba T and Levy JH. Coagulation abnormalities and thrombosis in patients with COVID-19. *Lancet Haematol* 2020; 7: 438-440.
- [20] Zhou F, Yu T, Du R, Fan G, Liu Y and Liu Z. Clinical course and risk factors for mortality of adult inpatients with COVID-19 in Wuhan, China: a retrospective cohort study. *Lancet* 2020; 395: 1054-62.